

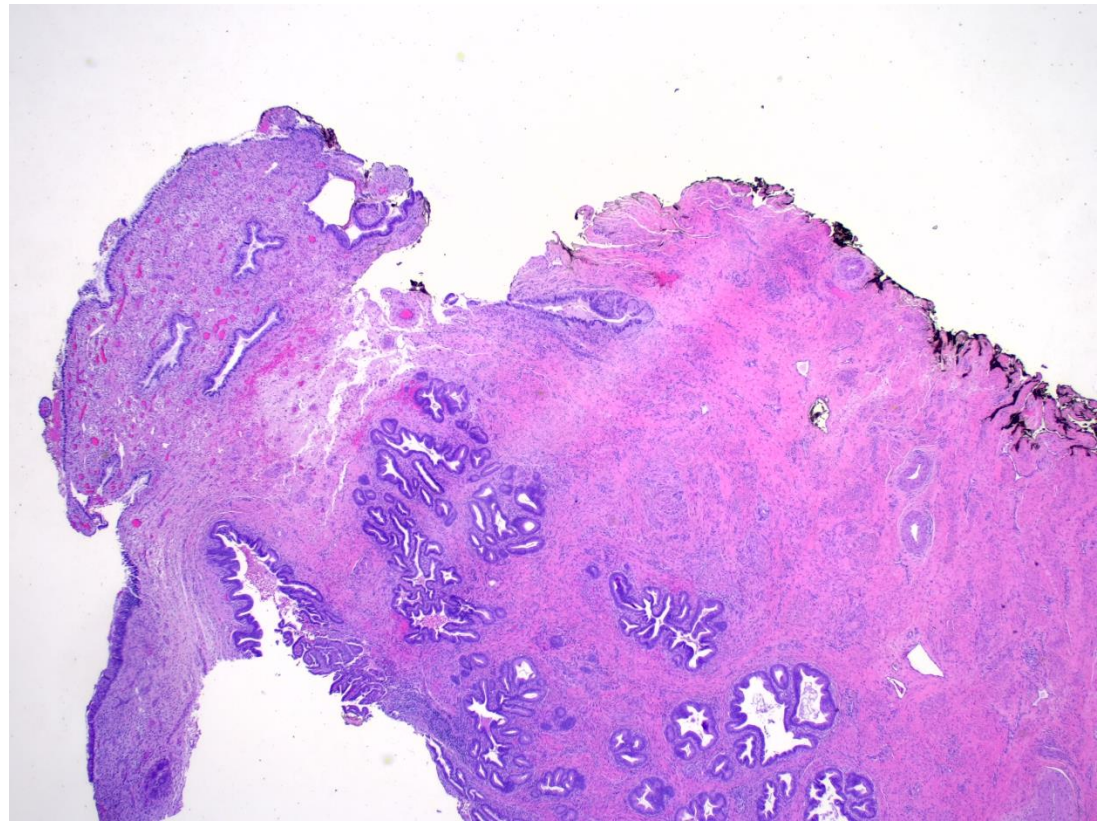
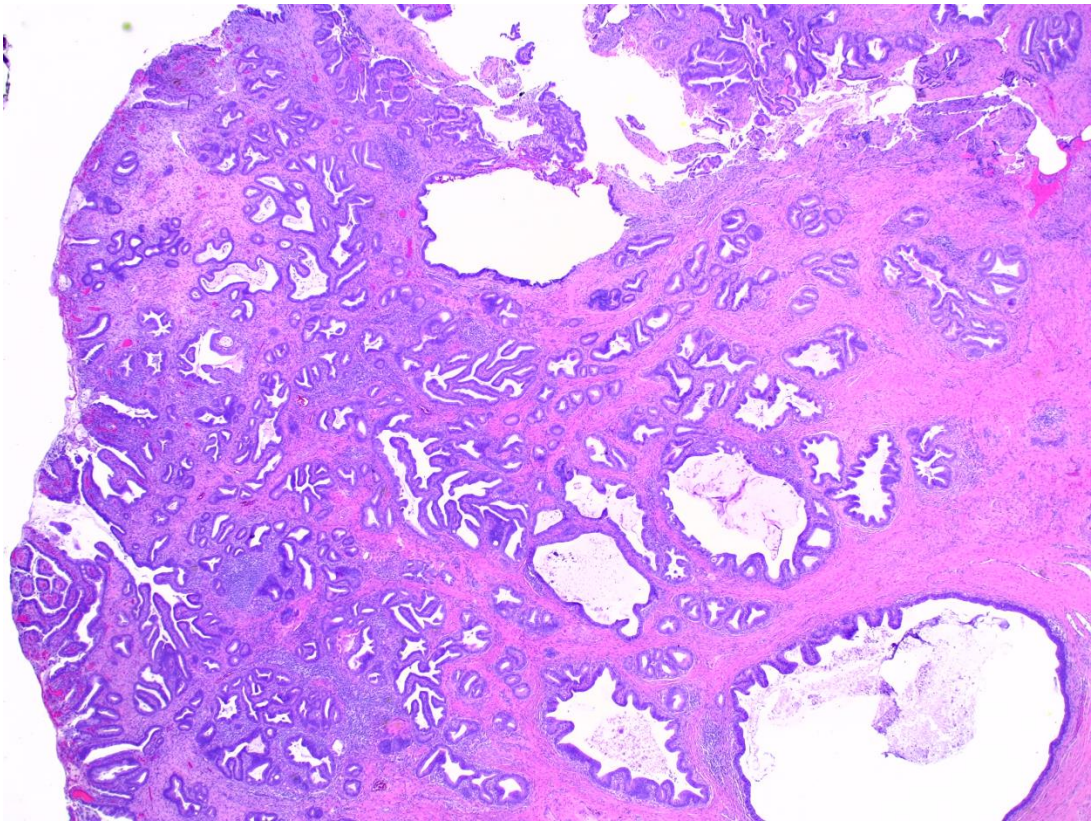
Picture Quiz

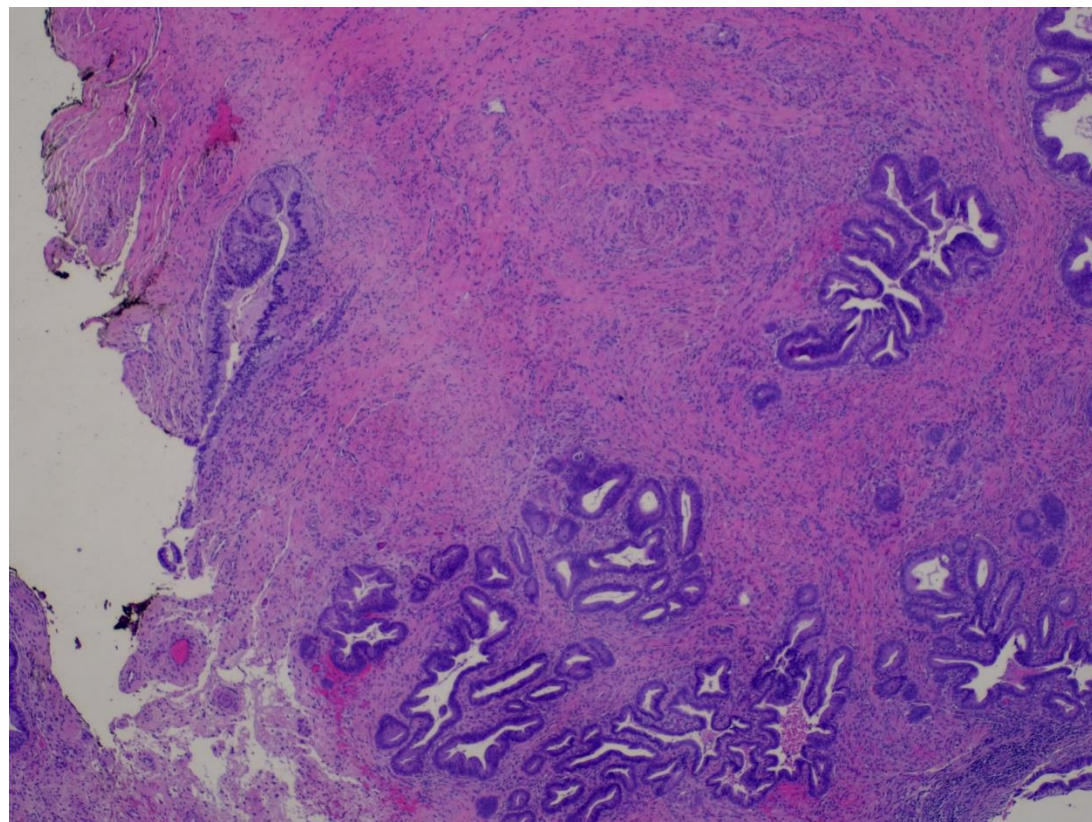
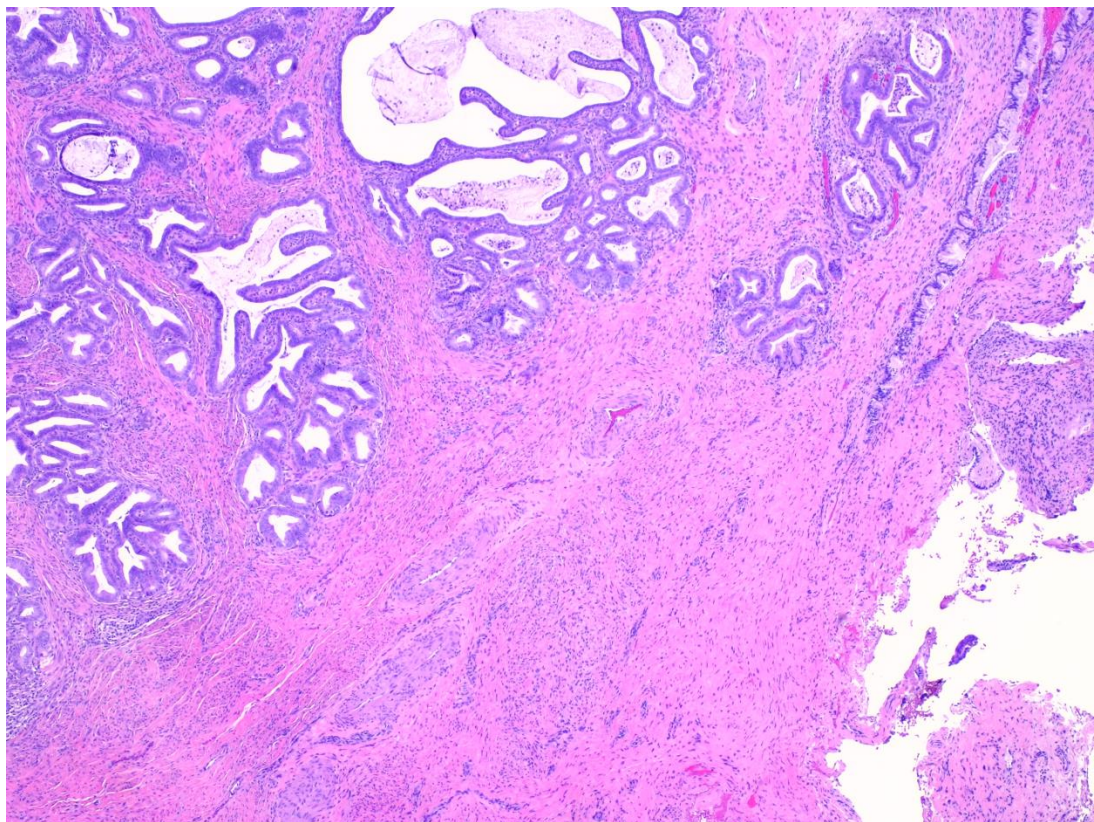
September 2023

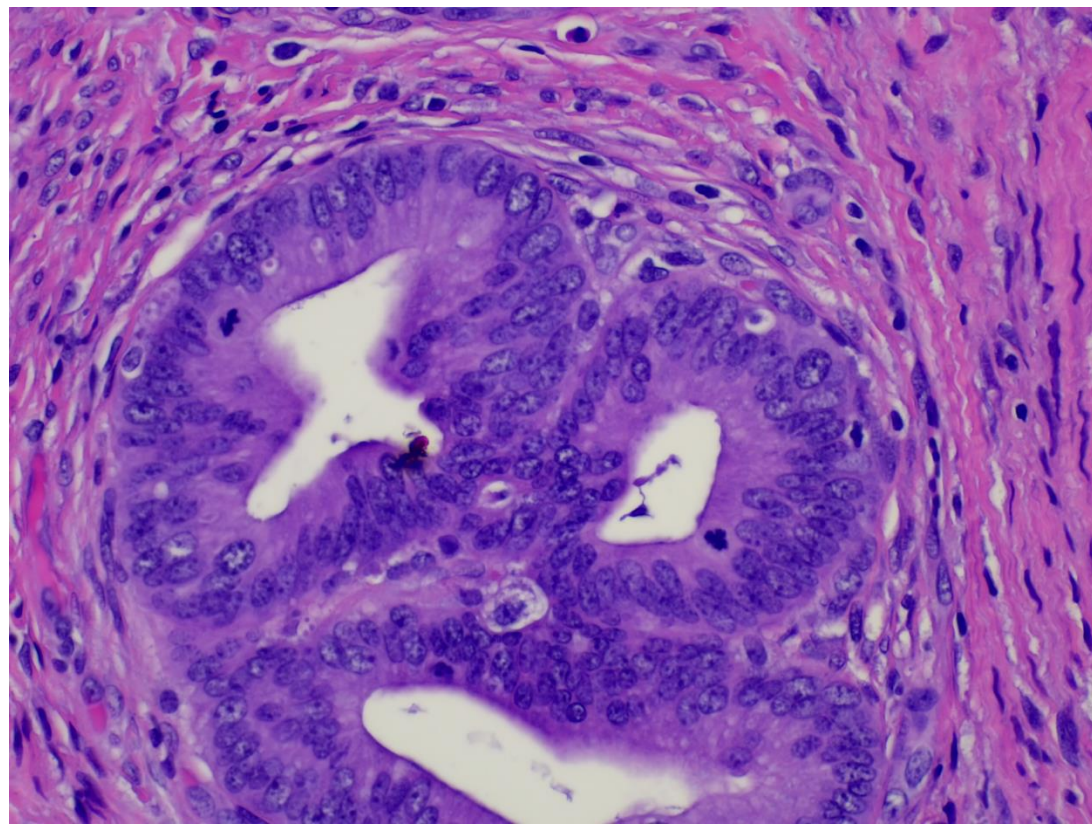
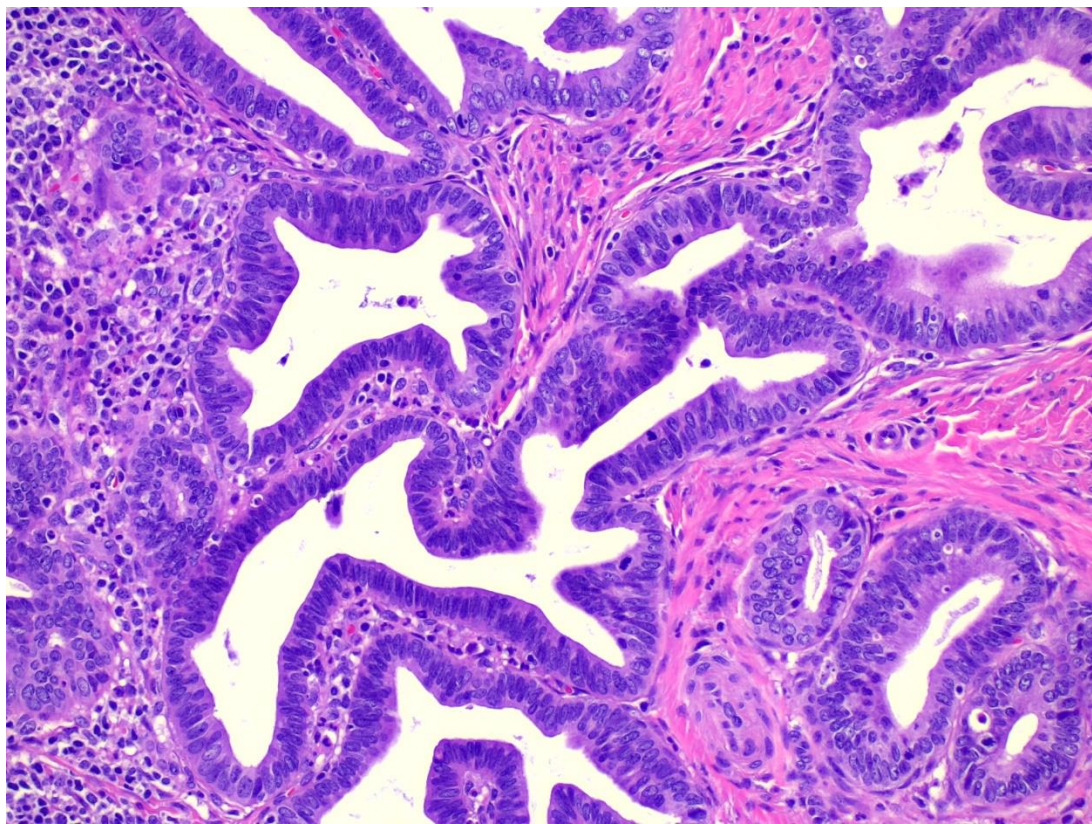
Ritu Bhalla, MD

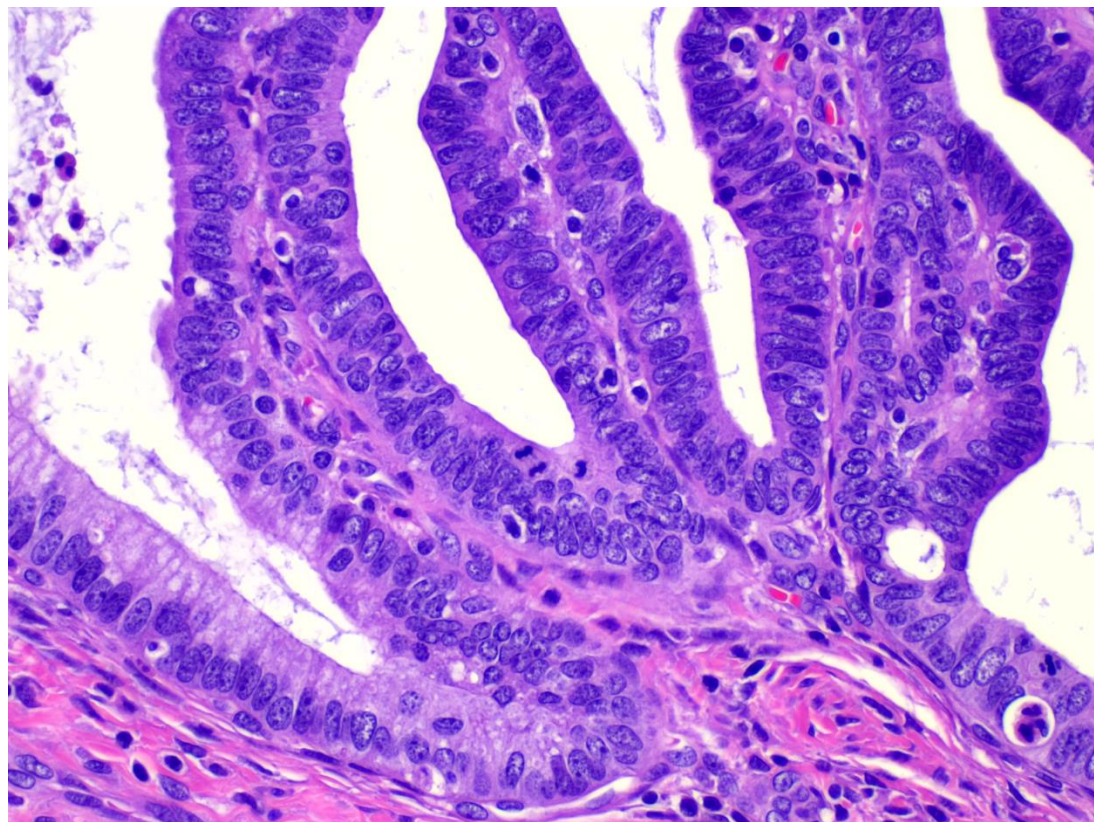
Case 1

- Cervical conization of a 33 year old female. Patient provides a history of dysplasia diagnosed at an outside hospital.
 - What is your diagnosis

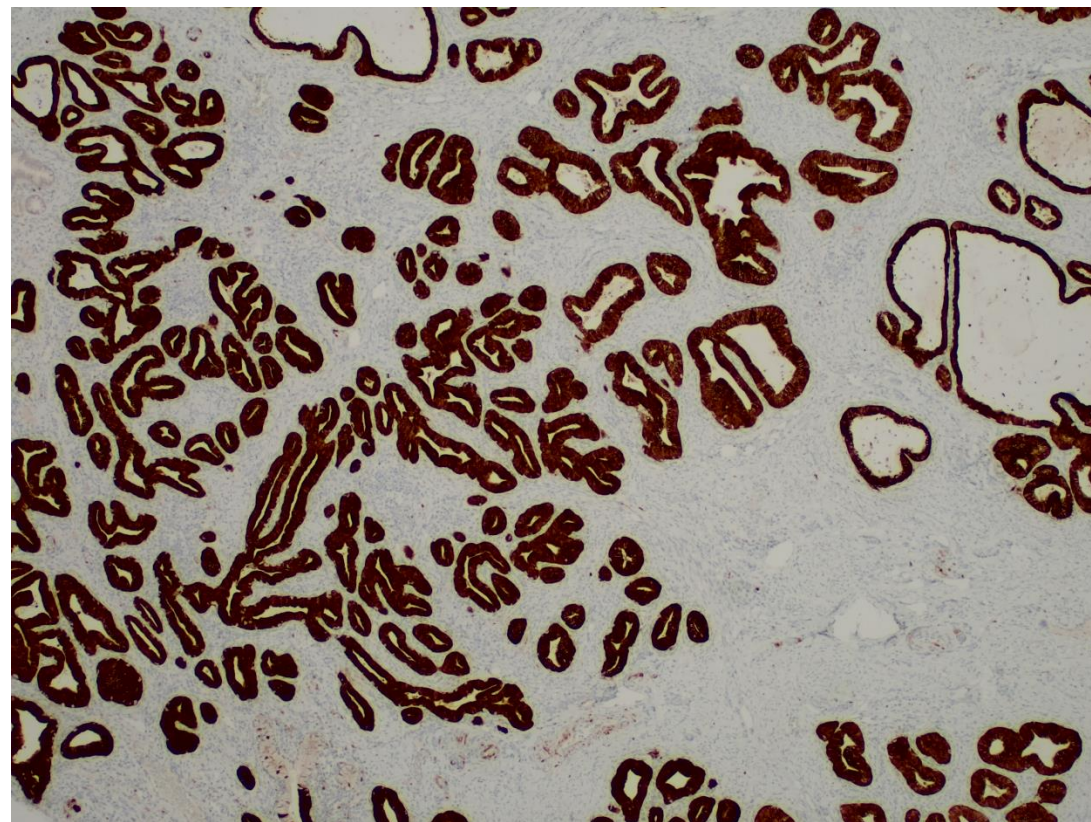








p16



Case 2

- 32 year old female, with left sided thyroidectomy for a TIRADS 5 diagnosis on imaging
- <https://pathpresenter.net/public/display?token=a3c6cff4>
- What is your diagnosis?

Case 3

- 35 year old female with bilateral ovarian masses, and multiple nodules on the peritoneum and bowel serosa
- <https://pathpresenter.net/public/display?token=c0e7d727>
- A p53 stain shows wild pattern of expression, and PAX8 is diffusely positive.
- What is your diagnosis?

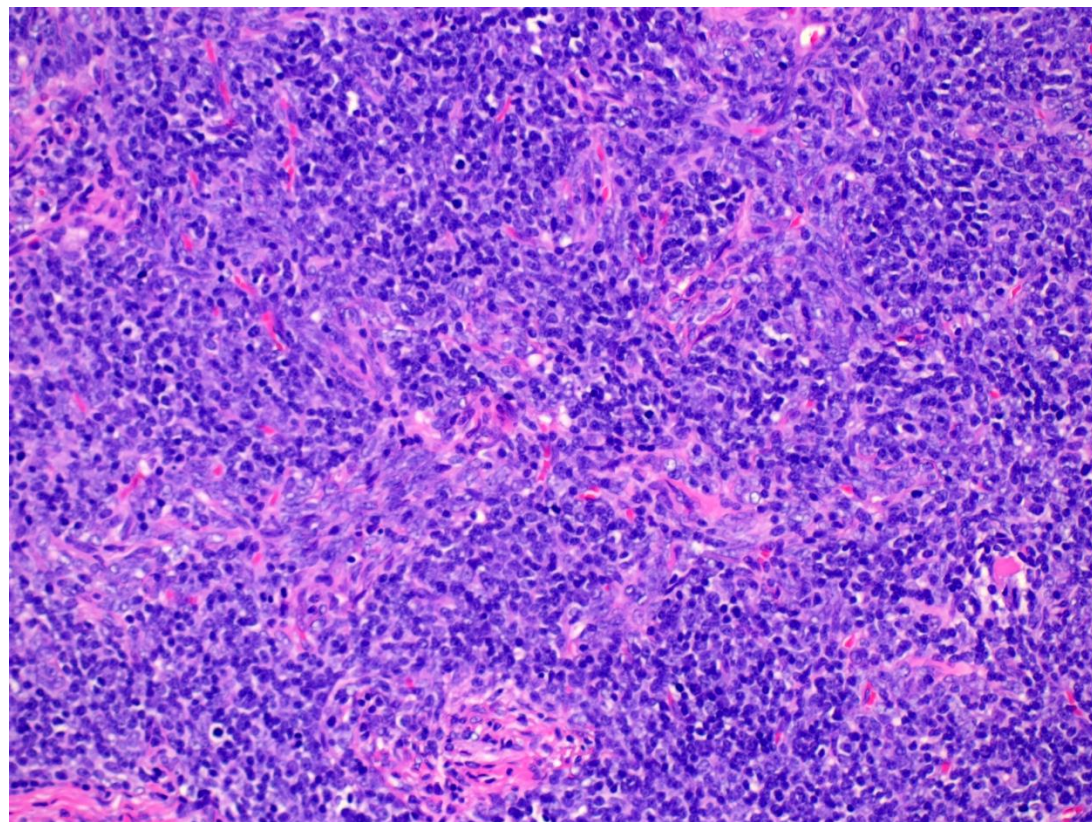
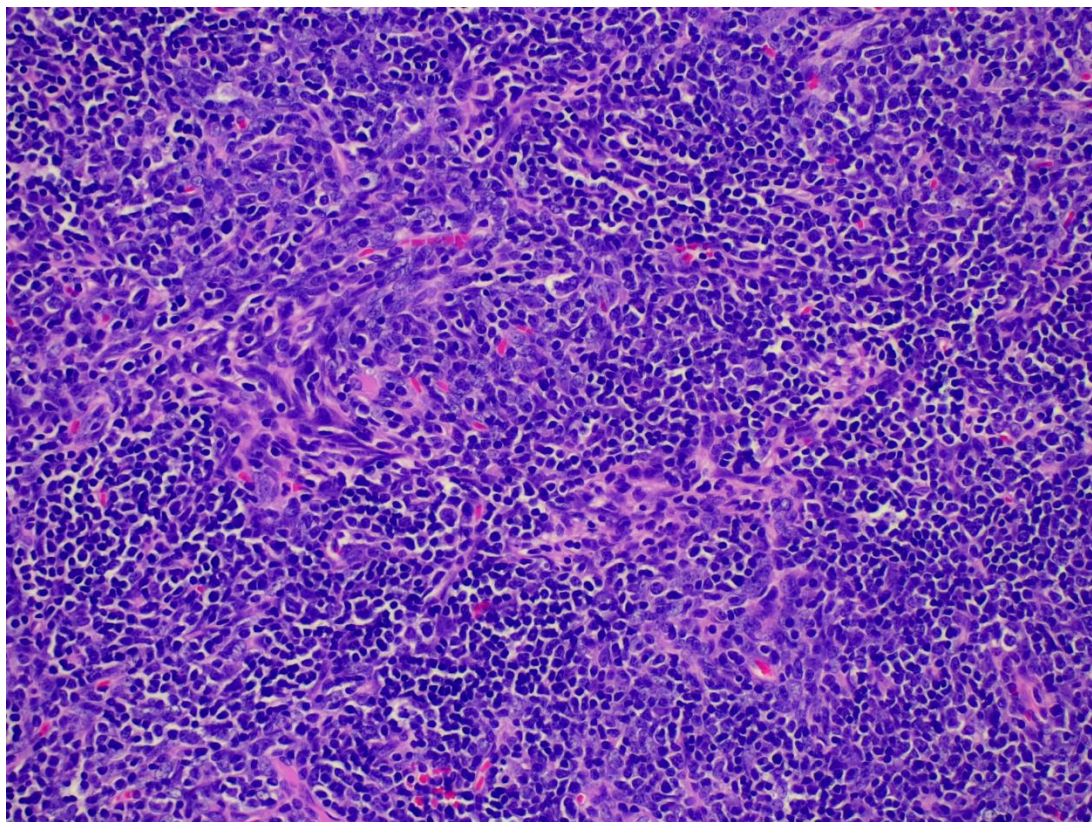
Case 4

- 26 year old male presenting with 4 cm retroperitoneal mass
- <https://pathpresenter.net/public/display?token=6dc9a3c1>
- [Beta catenin](#)

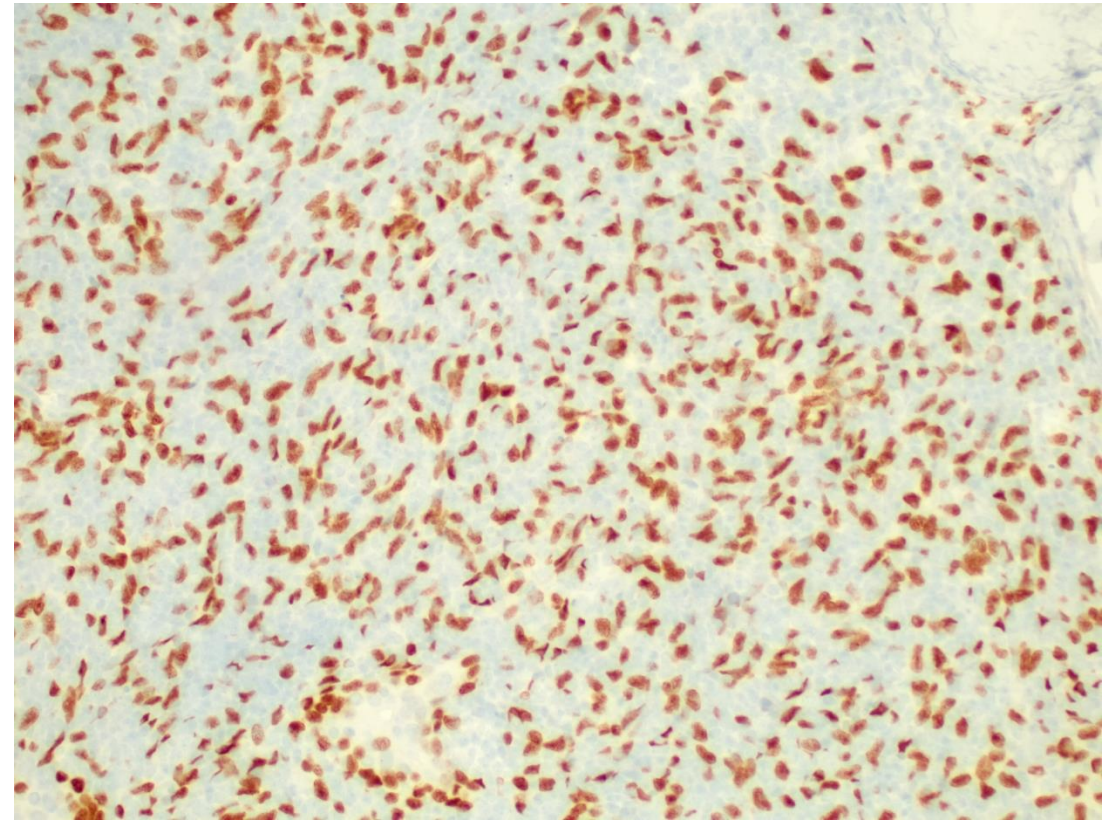
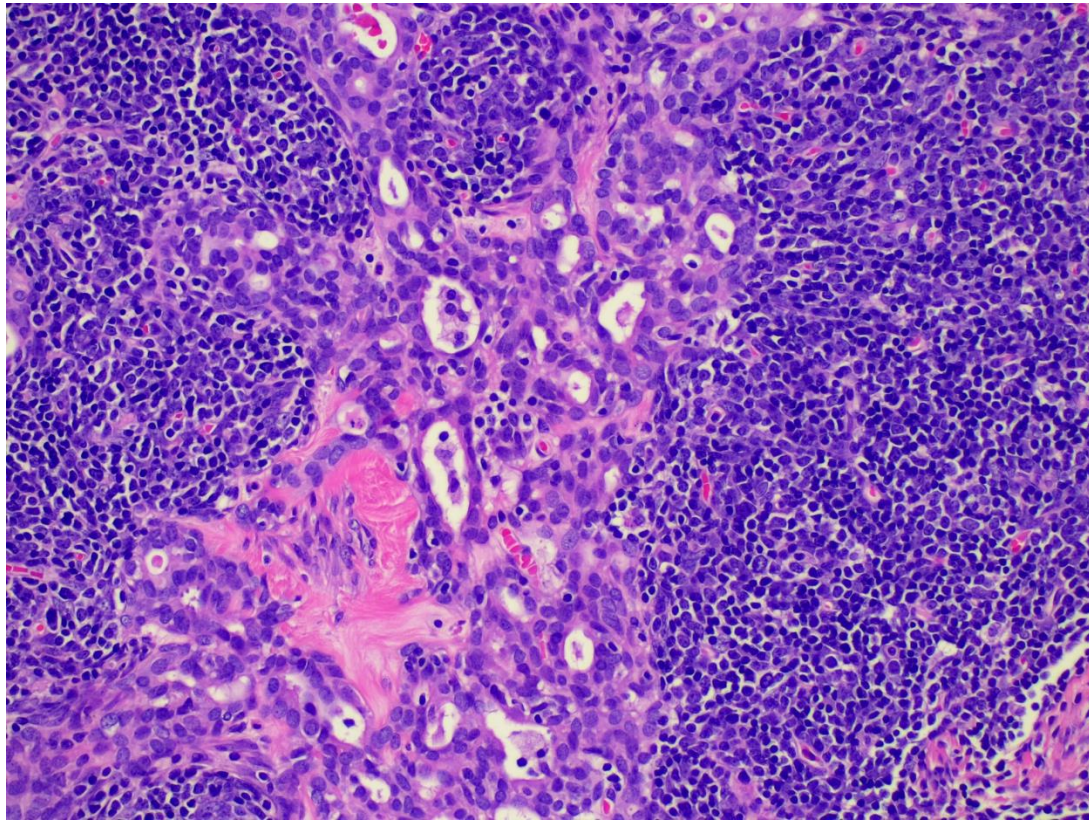
<https://pathpresenter.net/public/display?token=7b65201a>

Case 5

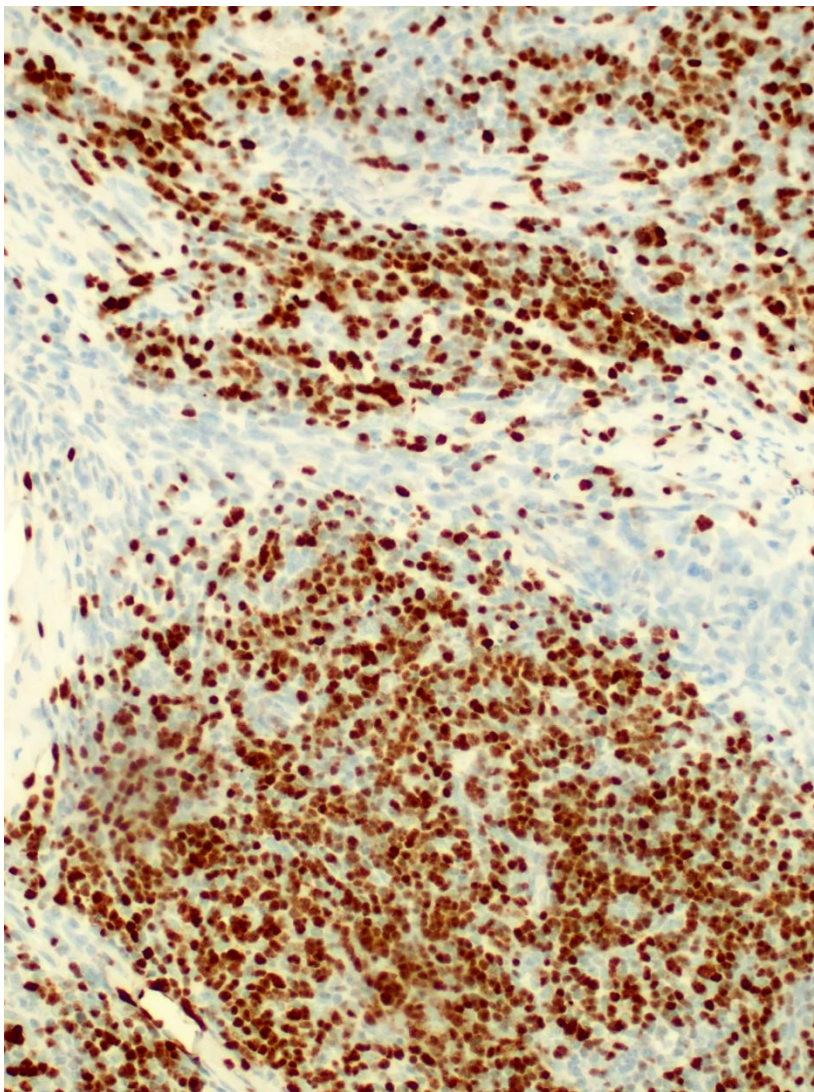
- 66 year old female with shortness of breath, follow up imaging showed mediastinal mass



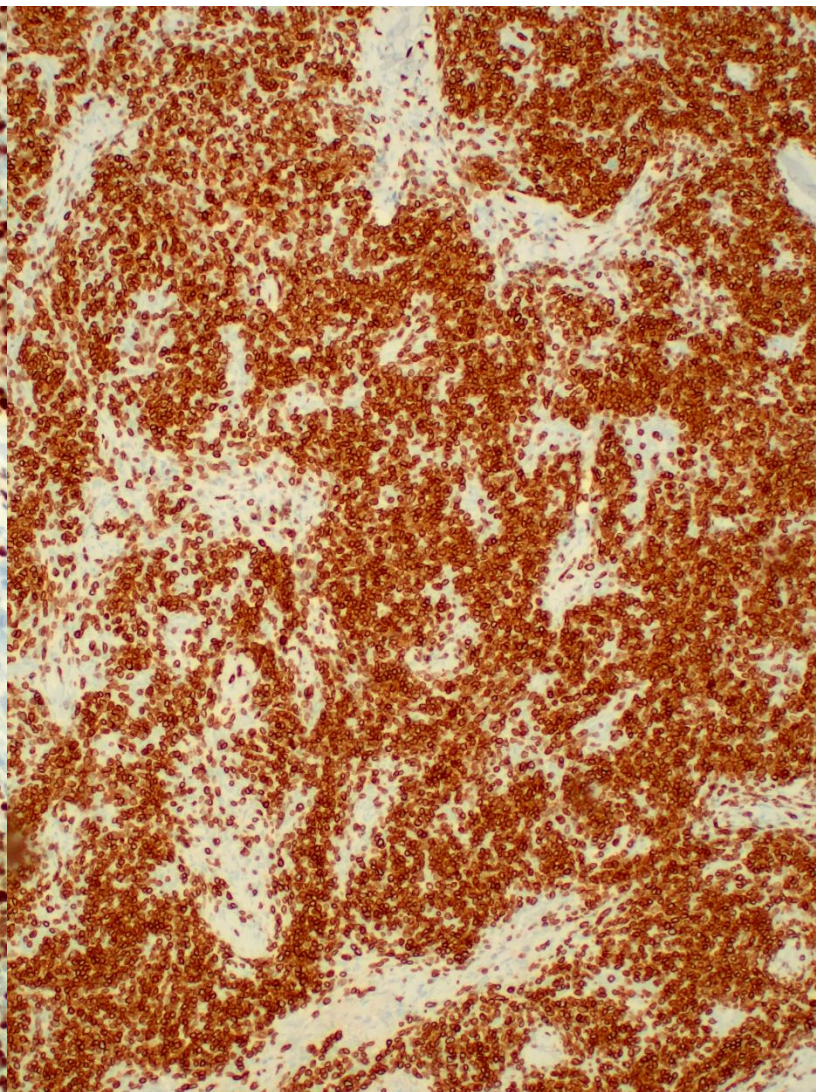
P63



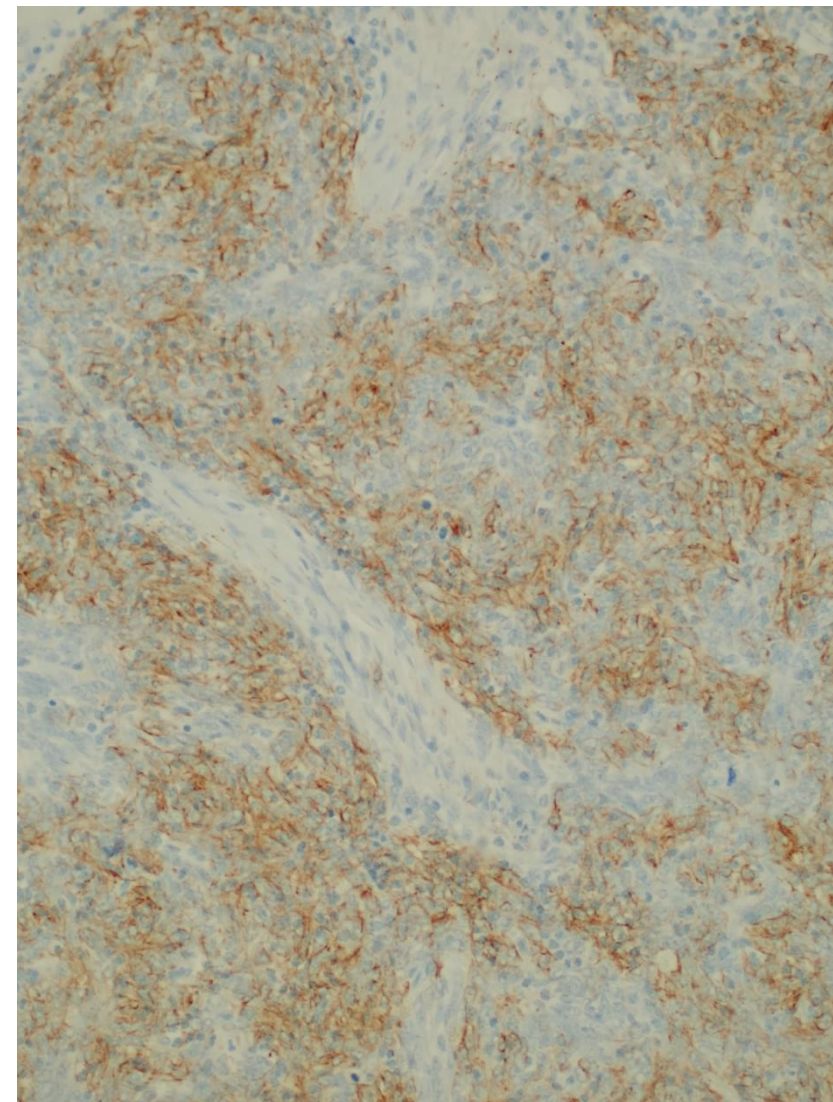
TdT



CD3



Pan CK



Case 6

- This person got lost and was found sitting near a sink drinking water. To whose office should we direct him (which office is his home)?

