

Pathology Picture Quiz

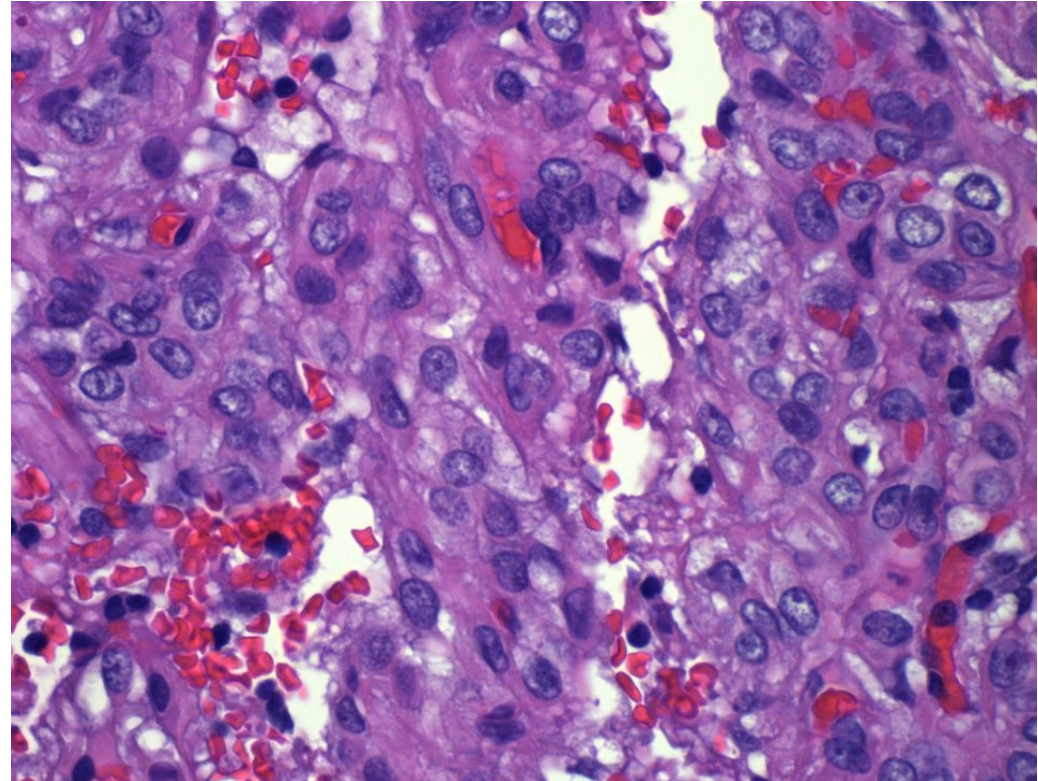
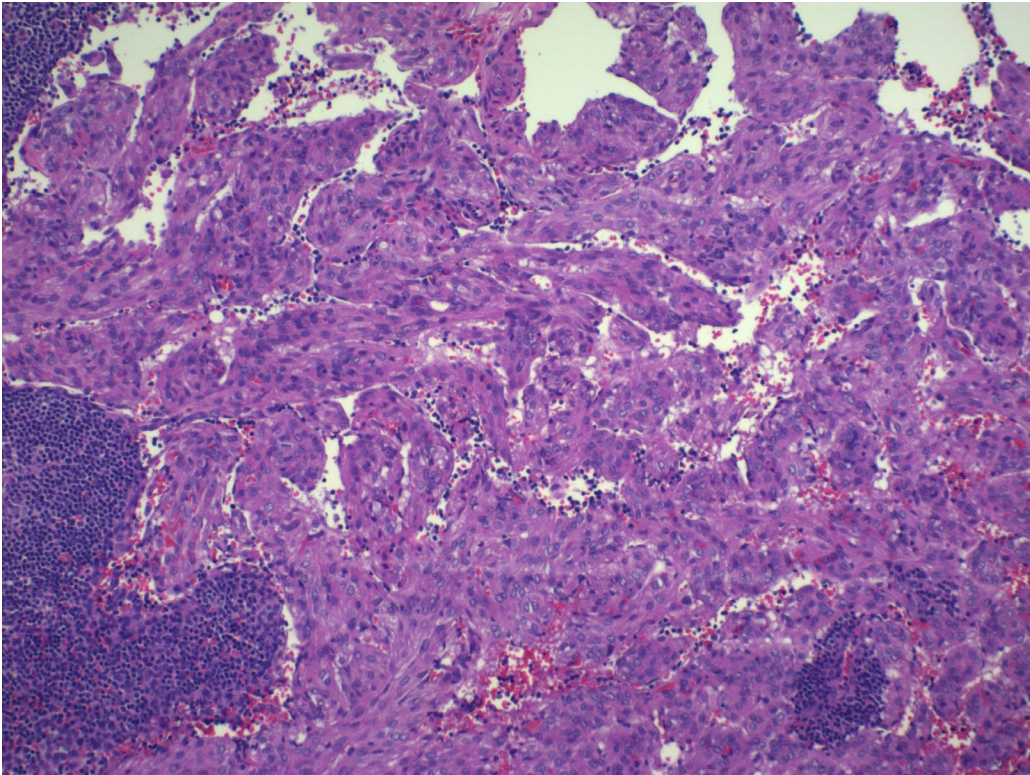
August 2022

Ritu Bhalla

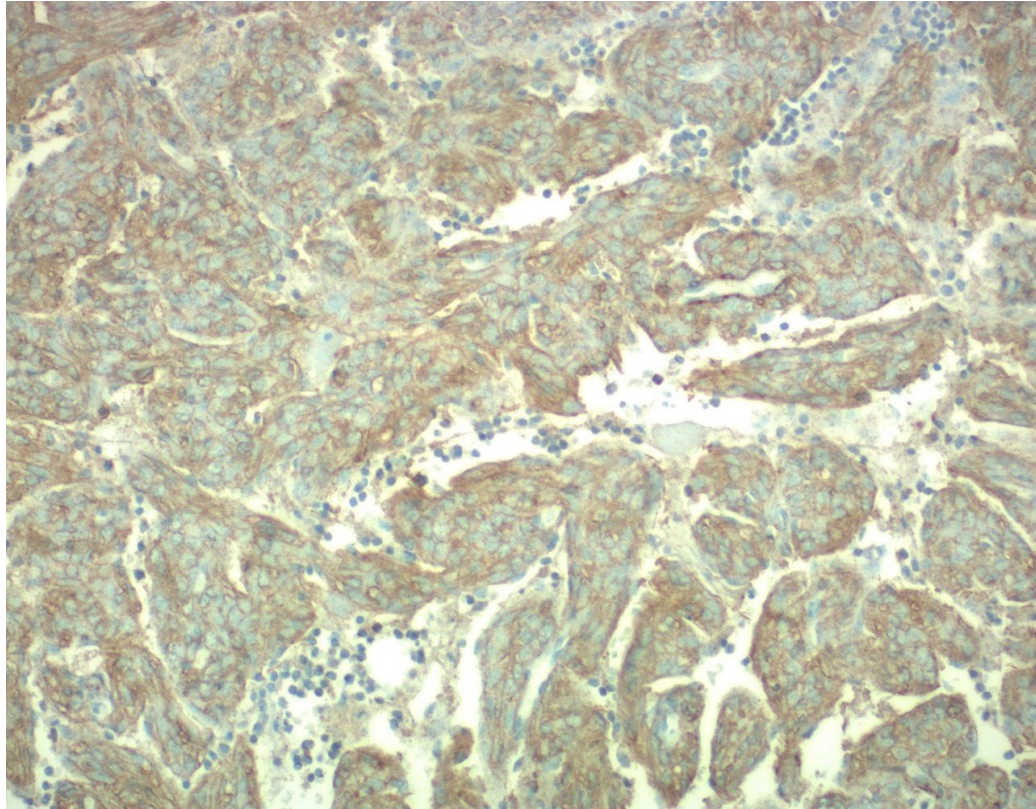
Case 1:

1. 37-year-old female, with incidental finding in pelvic lymph node, resected during laparotomy for motor vehicle accident (images set a). Two years later patient presented with renal tumor (images set b). Relatives from paternal side of family reported to have varying symptomatology presenting with seizures and behavioral problems; and issues involving different systems including skin, renal, eye, cardiac and pulmonary, in varying severities.

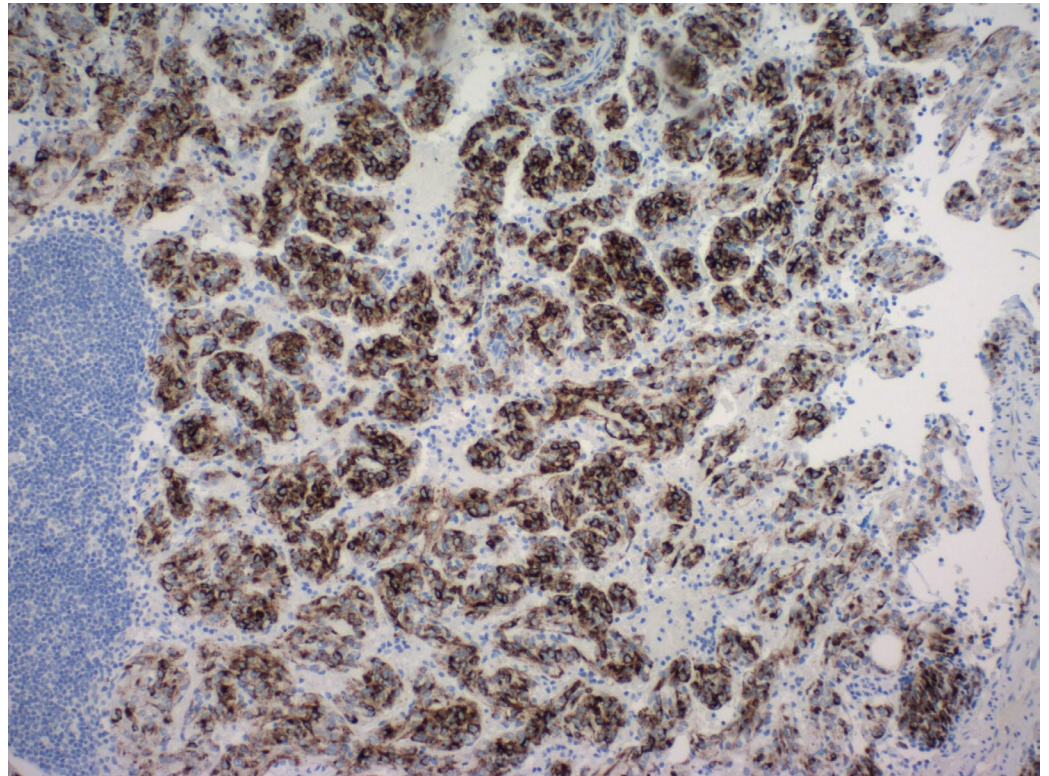
1A:Lymph node (immunostains on next slide)
What is your diagnosis??



1A:

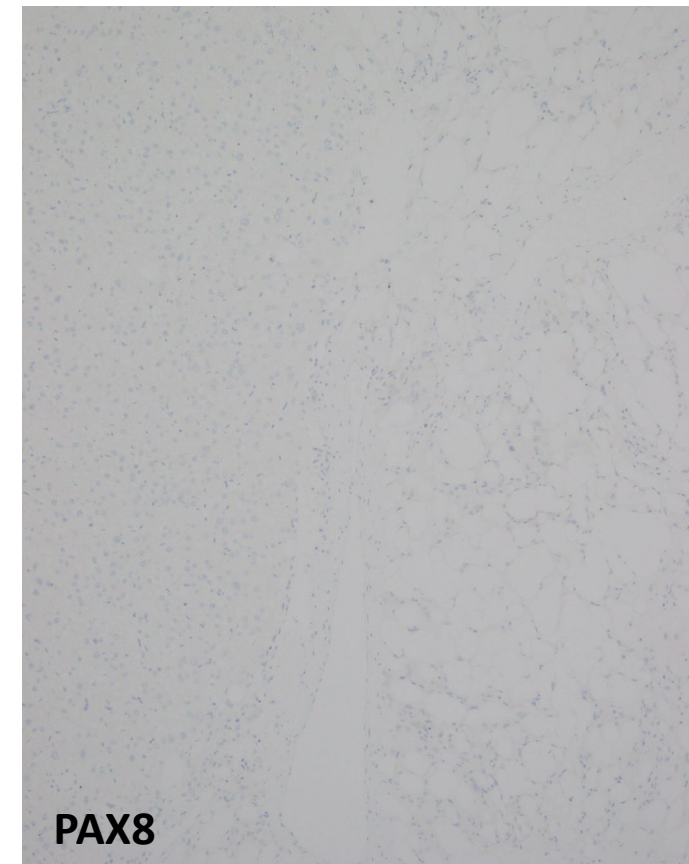
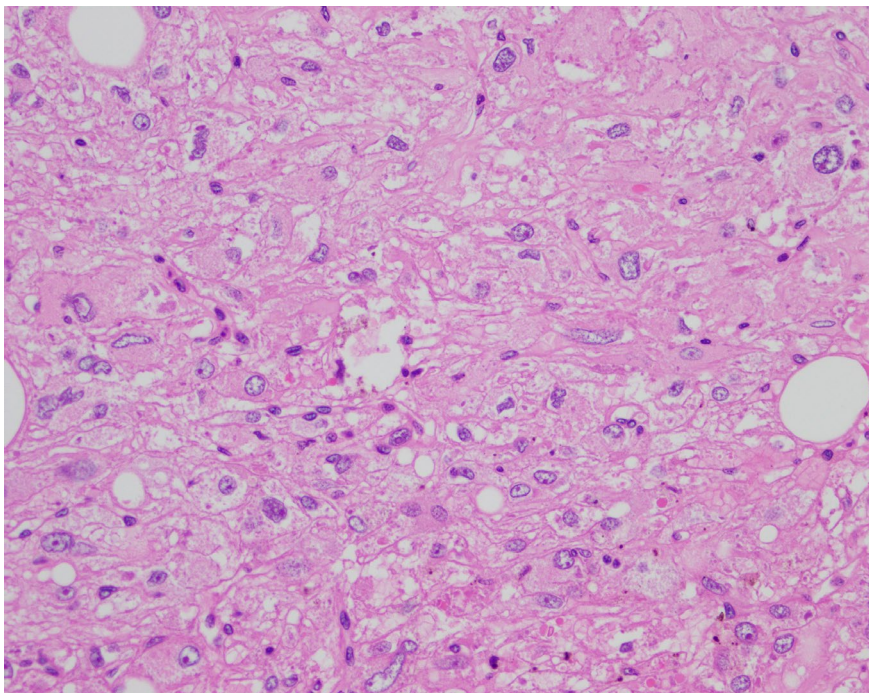
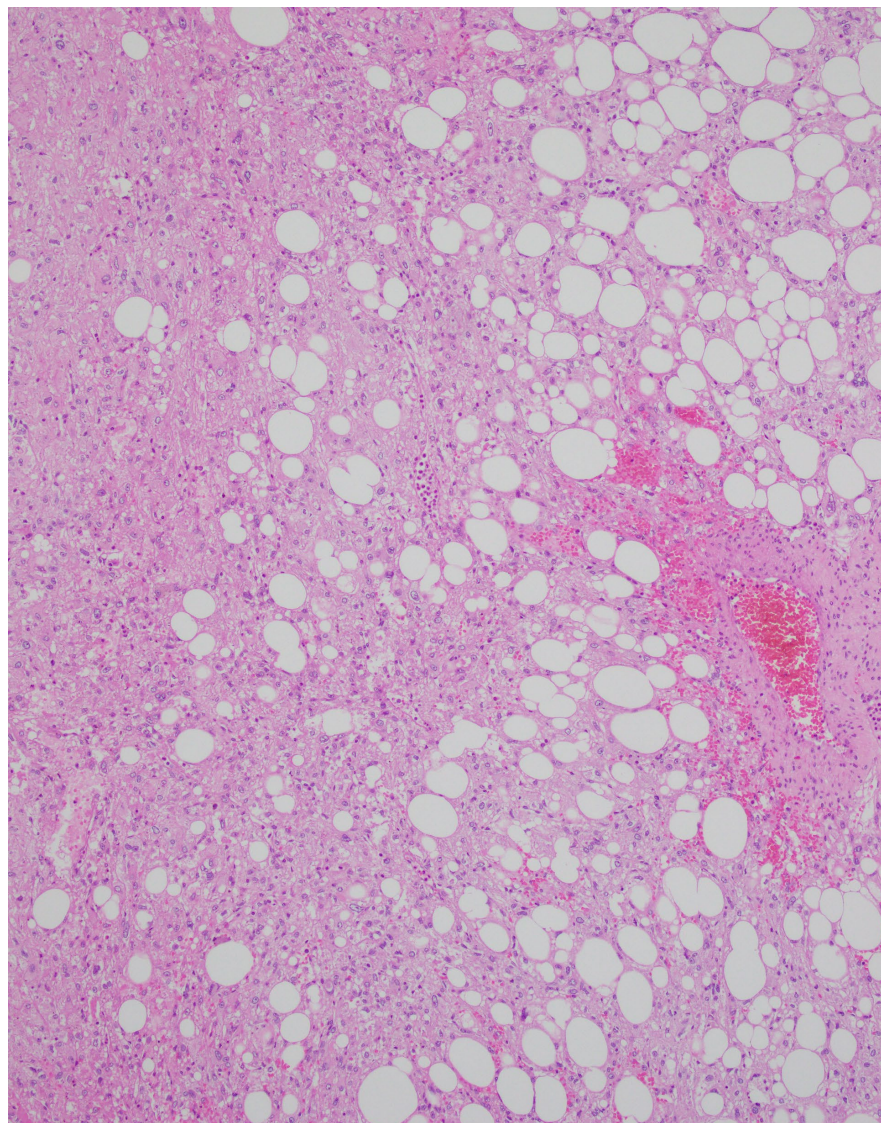


SMA



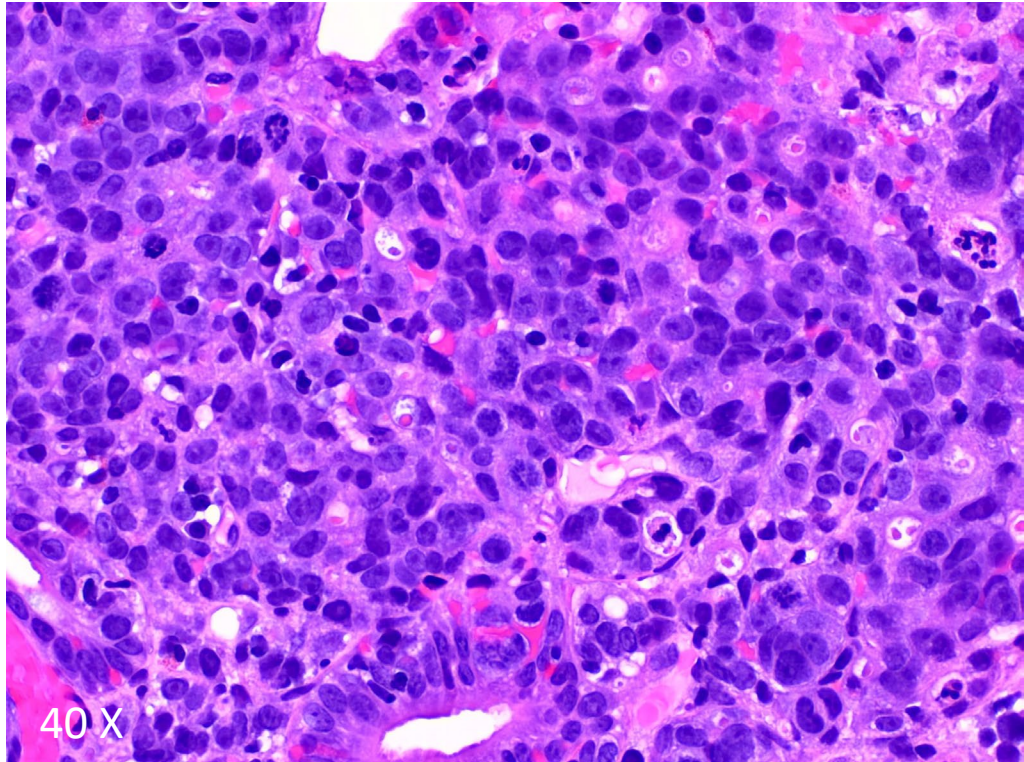
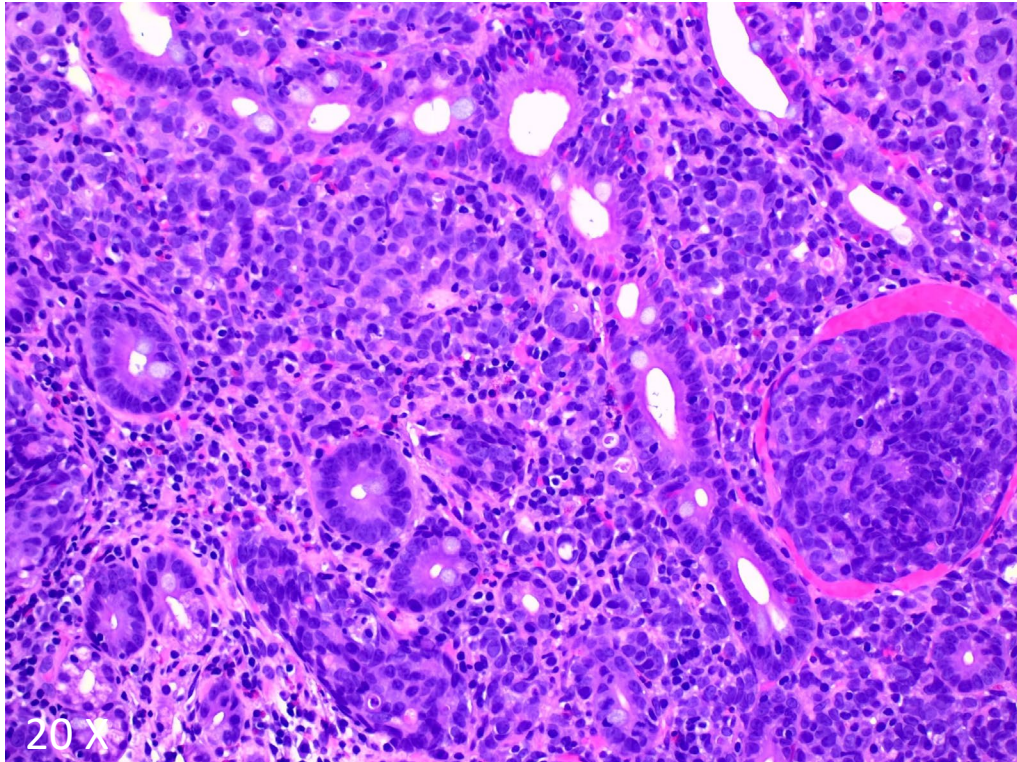
HMB-45

1B. Kidney. What is your diagnosis

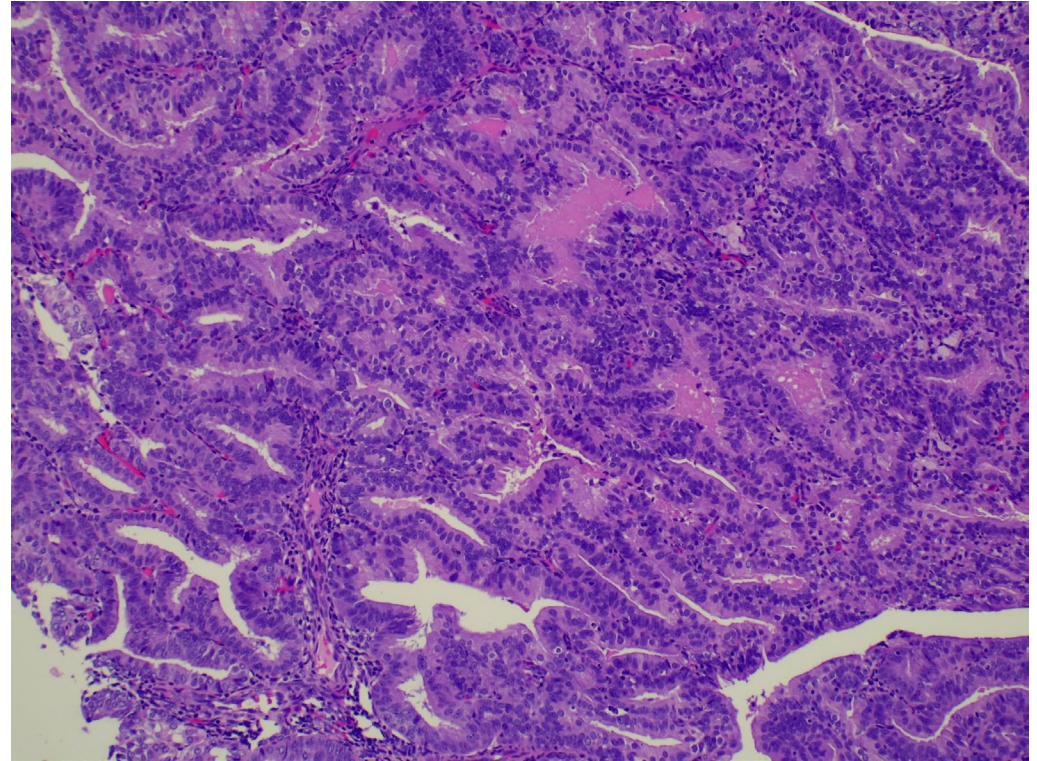
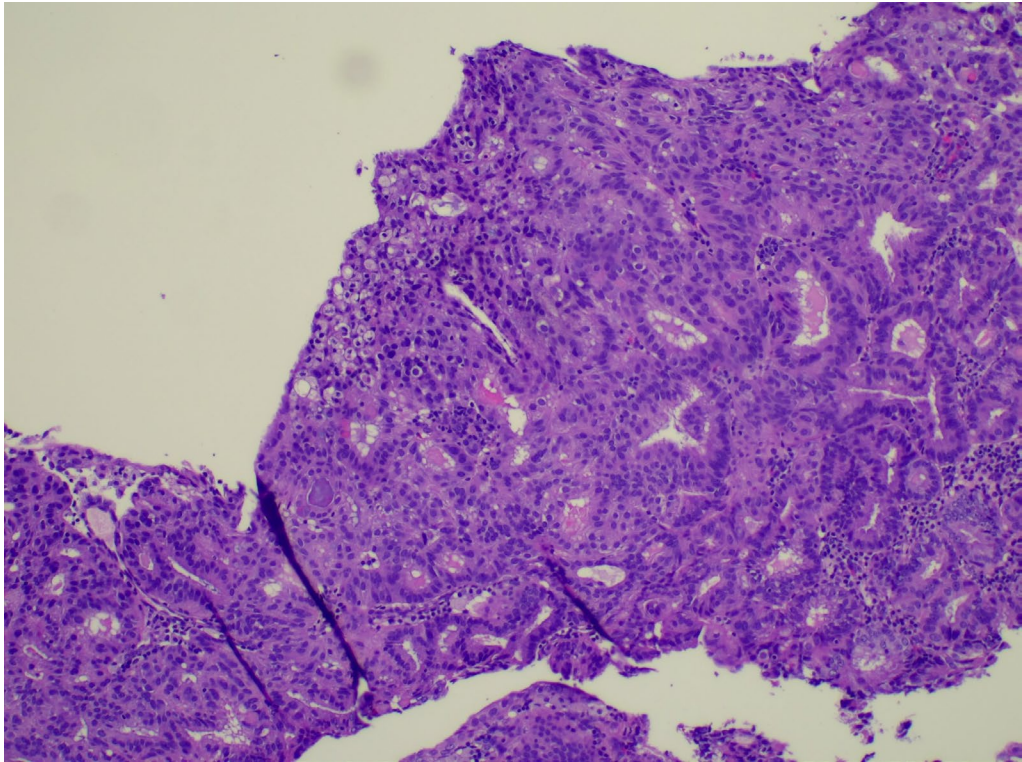


Case 2: 72-year-old woman presents with abdominal pain, vomiting and anemia. What is your diagnosis?

- a. Chronic gastritis
- b. Gastric carcinoma
- c. Gastric lymphoma
- d. Gastric xanthoma

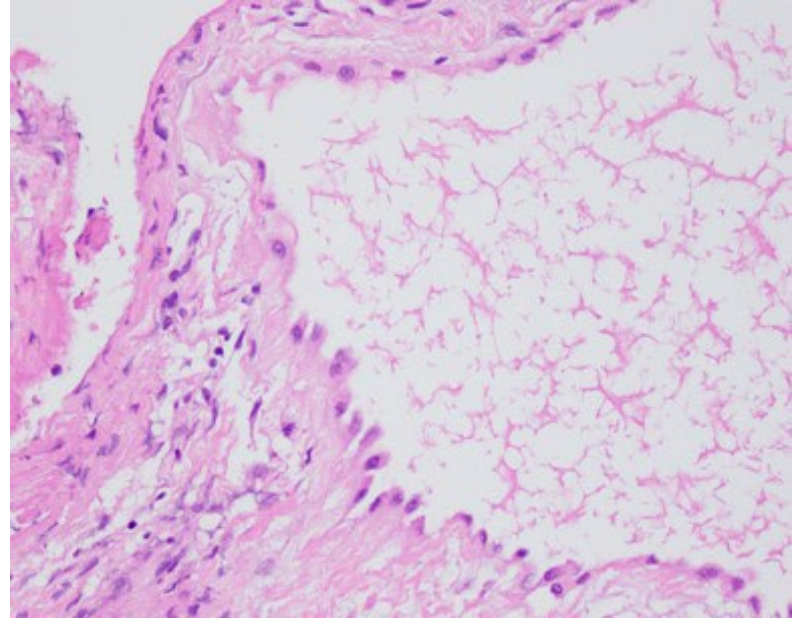
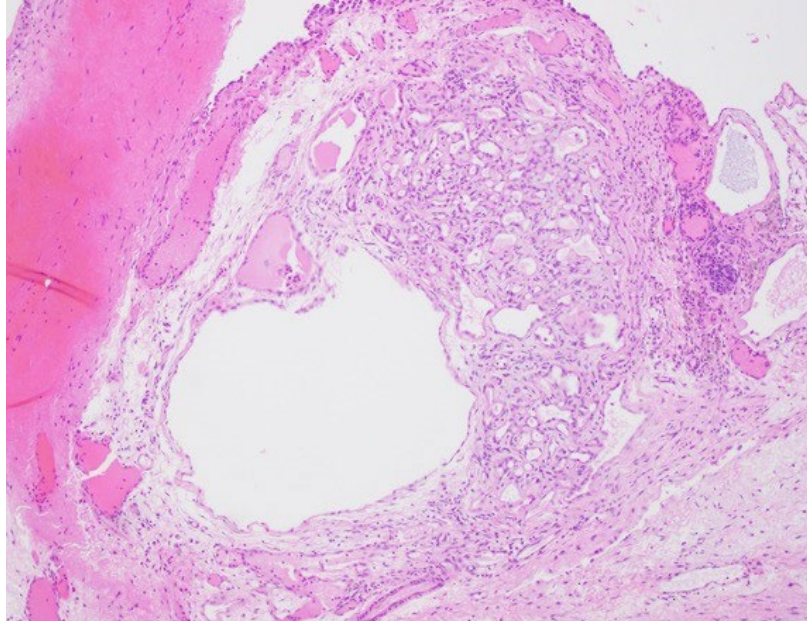
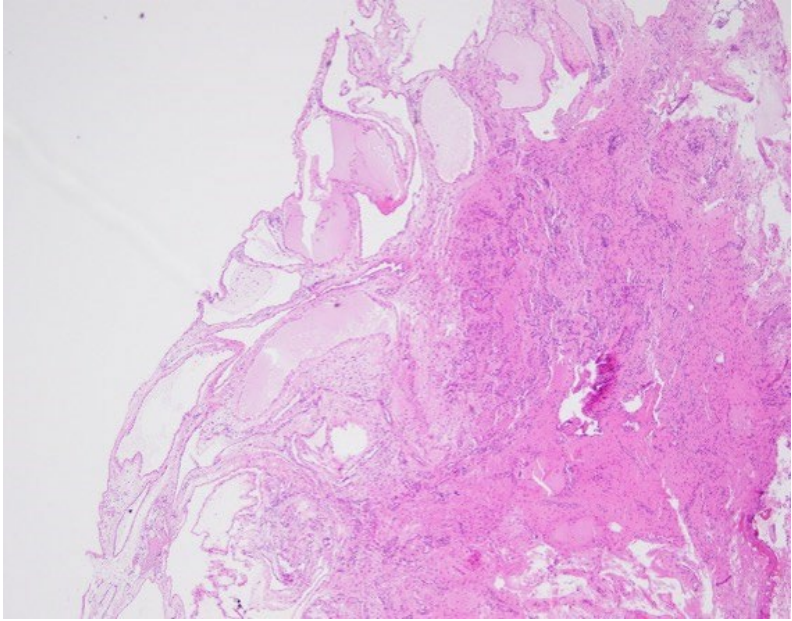


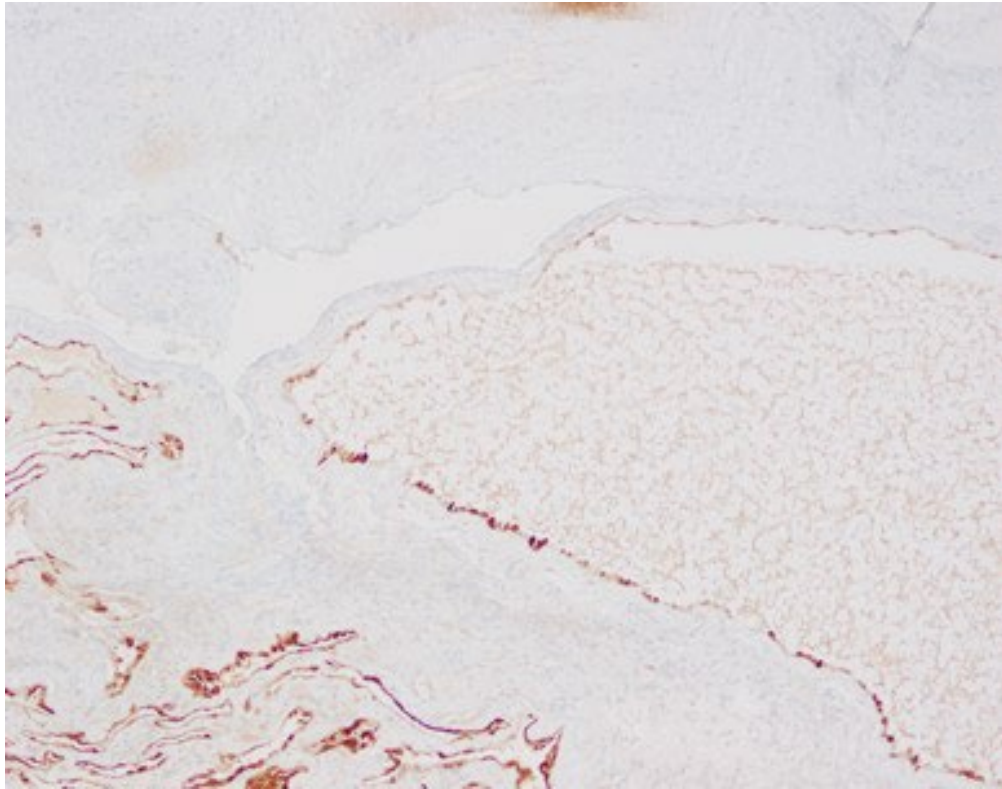
Case 3: 64-year-old woman presenting with abnormal uterine bleeding. What is your diagnosis?



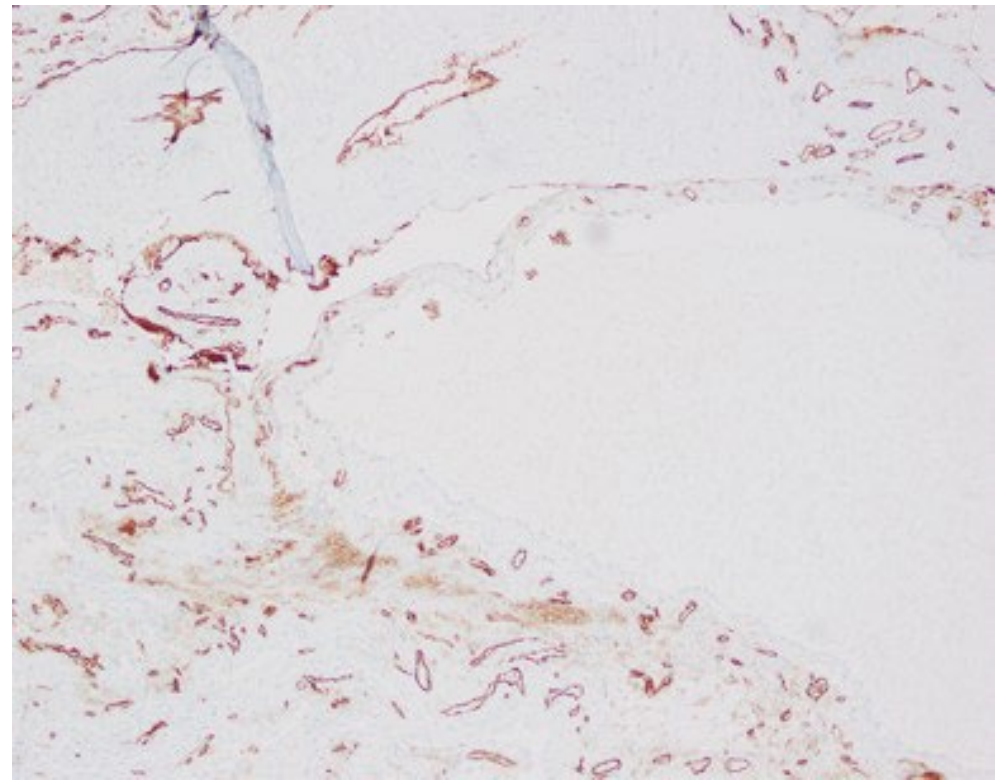
Case 4:

During oophorectomy of a 27-year-old female for a benign ovarian tumor, surgeon observed multiple lesions scattered on the serosal aspect of her bowel, bladder wall and peritoneum.





Calretinin



CD31

Case 4

- What is your diagnosis?
- a. Lymphangioma
- b. Endometriosis
- c. Malignant mesothelioma
- d. Multicystic mesothelioma of peritoneum



Image 5

The tree in the center is surrounded by coffee and black pepper plants. Which arrow points coffee and which one points black pepper????

Blue arrow?

Brown arrow?