

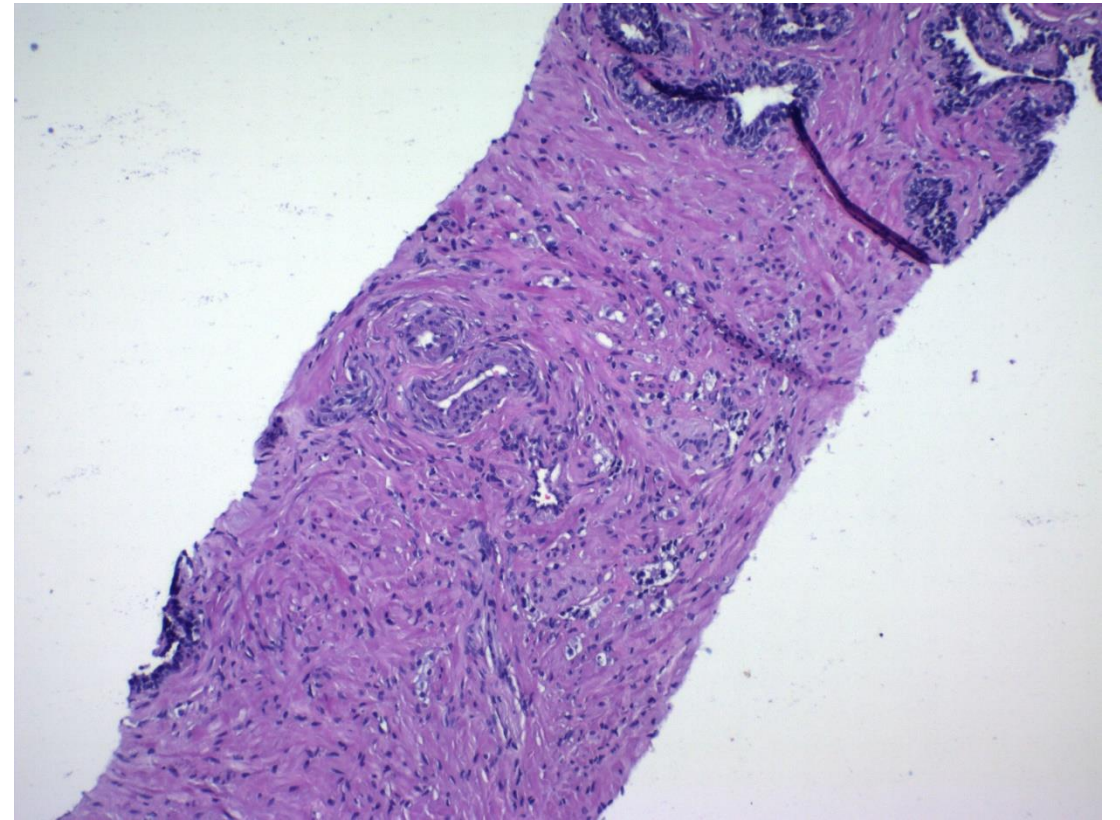
Quiz 3

2019-20

Ritu Bhalla, MD

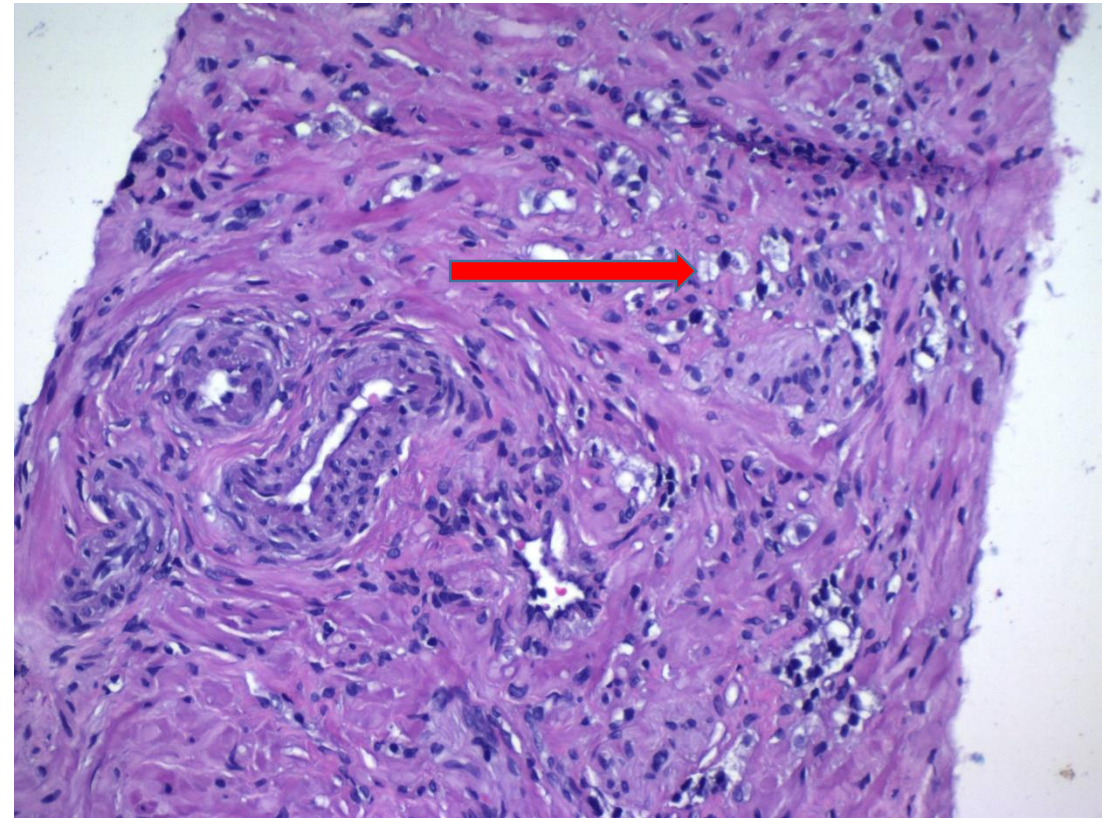
Questions 1-3

- The picture represents prostate biopsy of a 68 year old male with a history of Gleason score $4+5=9$ prostate cancer treated by radiation therapy.



Question 1

- How would you expect the cells (with arrow) to react?
 1. CD68 positive
 2. CD45 positive
 3. GATA3 positive
 4. Pan-cytokeratin positive

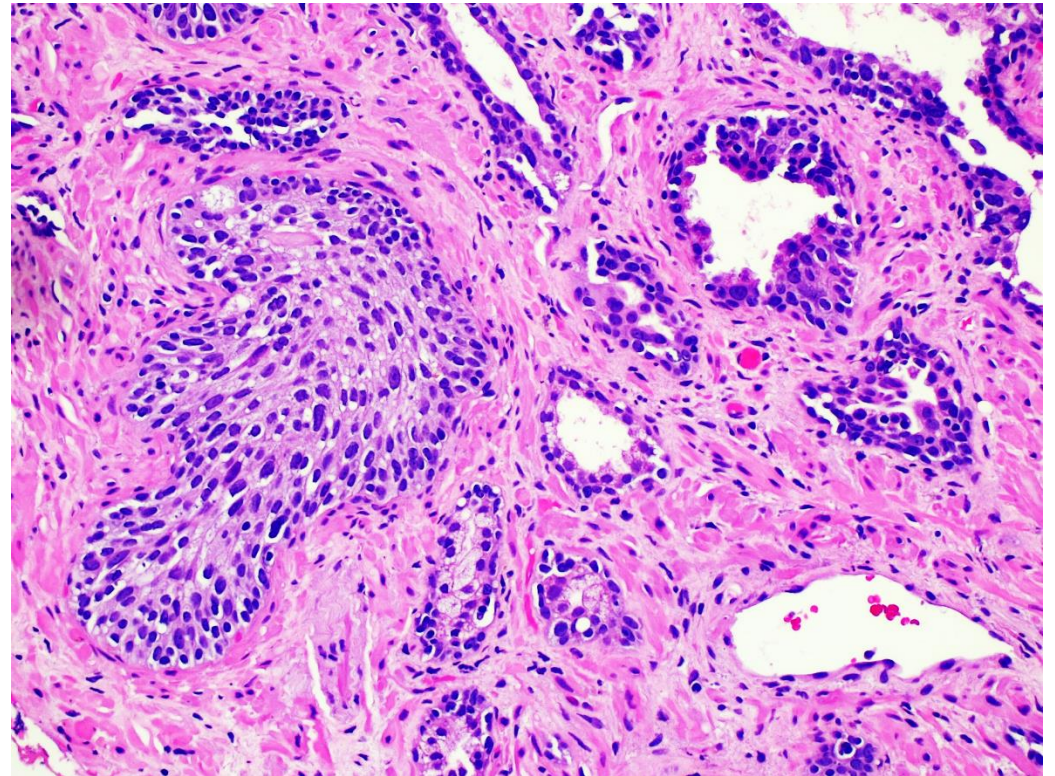
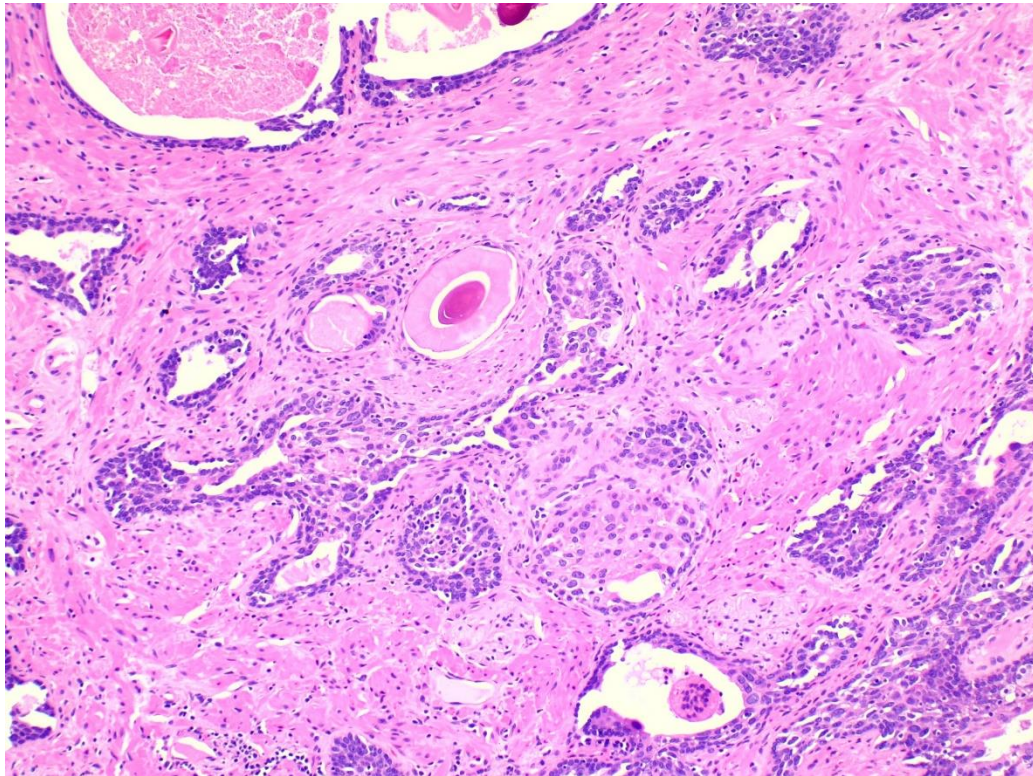


Question 2

- What is your diagnosis?
 1. Scattered histiocytes
 2. Recurrent Gleason 5+5=10 prostatic adenocarcinoma
 3. Recurrent prostatic adenocarcinoma with therapy related changes.
 4. Minute focus of lymphoma

Question 3

Additional pictures from the same patient at other areas:

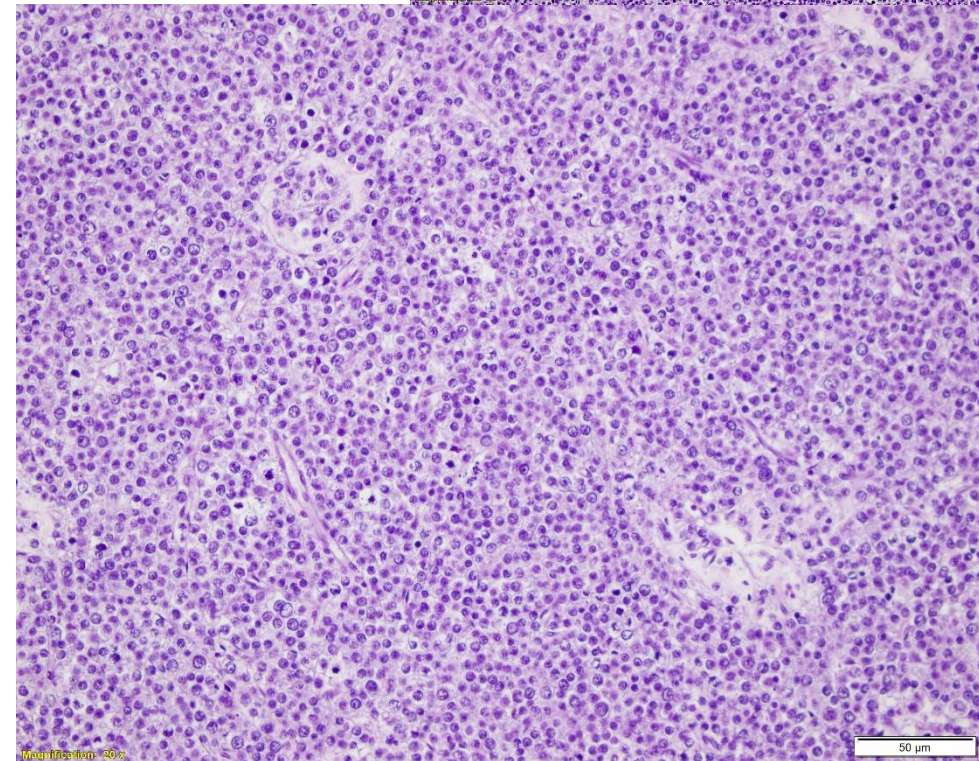
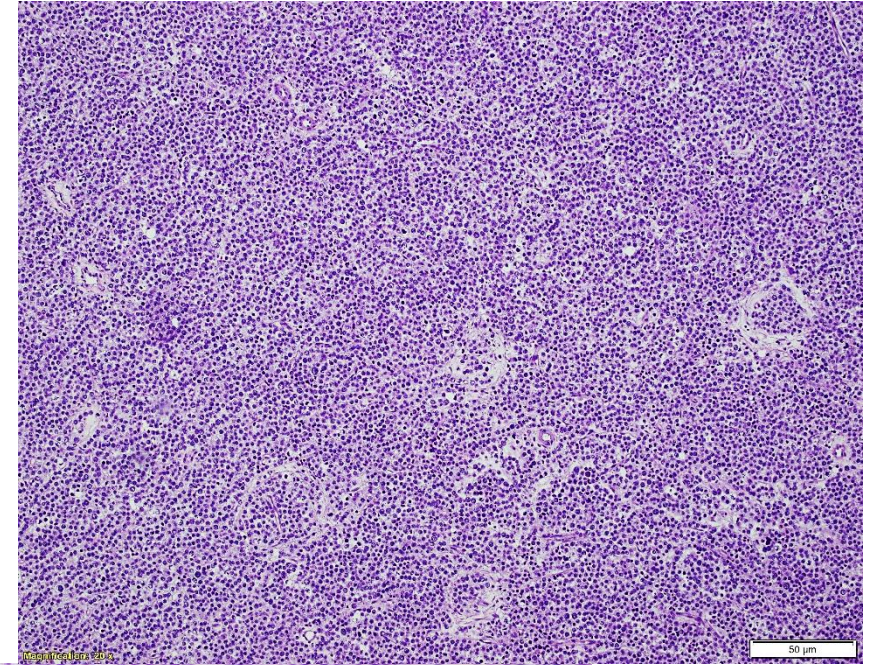


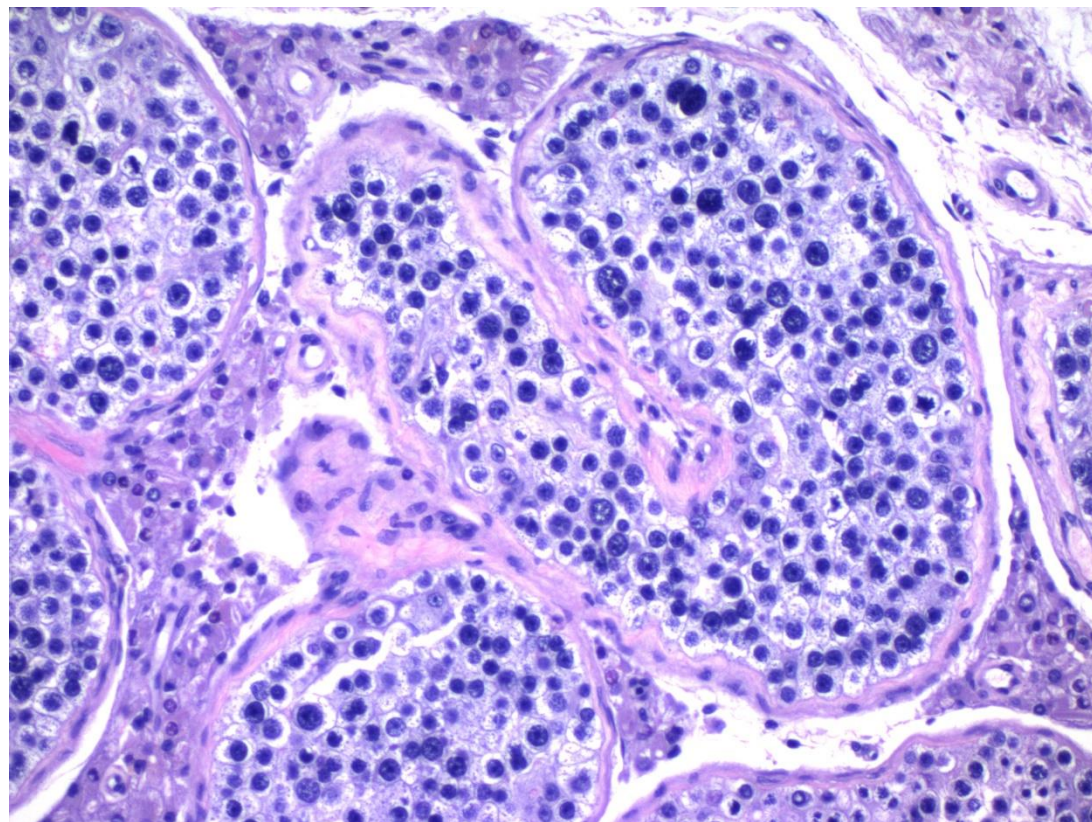
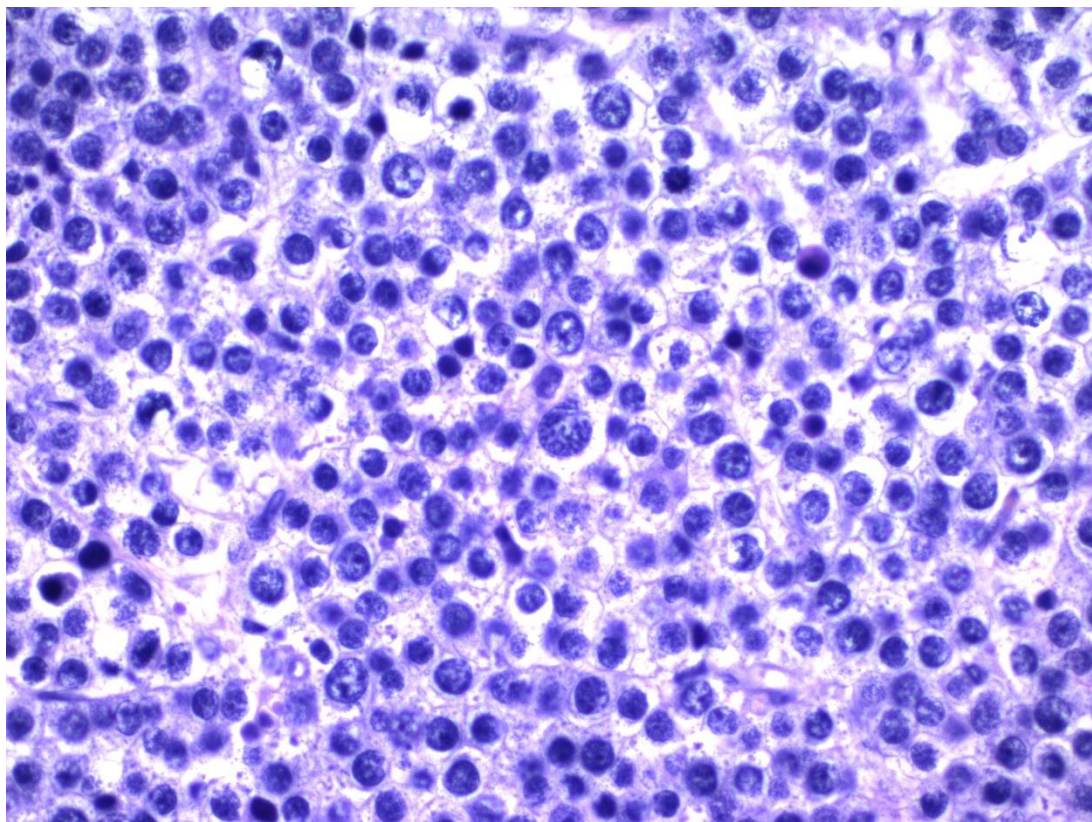
Question 3

- What is your diagnosis?
 1. Benign prostatic tissue, negative for malignancy
 2. High grade prostatic intraepithelial neoplasm
 3. Prostatic adenocarcinoma, with radiation associated changes
 4. Prostatic adenocarcinoma and concurrent urothelial carcinoma

Questions 4-5

- 64 year old male with mild testicular enlargement. After appropriate imaging and work up the patient underwent radical orchiectomy, histology of the lesion as shown in the images





Question 4

- What immunohistochemical marker, is expected to be expressed by this neoplastic cells?
 1. PLAP
 2. CD117
 3. D2-40
 4. CD30
 5. Glypican 3

Question 5

- The neoplasm is associated with one of the following features
 1. Elevated AFP
 2. Excellent prognosis
 3. Isochromosome 12p abnormalities
 4. Germ cell neoplasm in situ

Serious questions!!!!

Match the following Quarterbacks with their past or present teams

- 6. Peyton Manning
- 7. Matt Ryan
- 8. Ryan Fitzpatrick
- 9. Drew Brees
- A. San Diego Chargers
- B. Denver Broncos
- C. Atlanta Falcons
- D. Miami Dolphins