

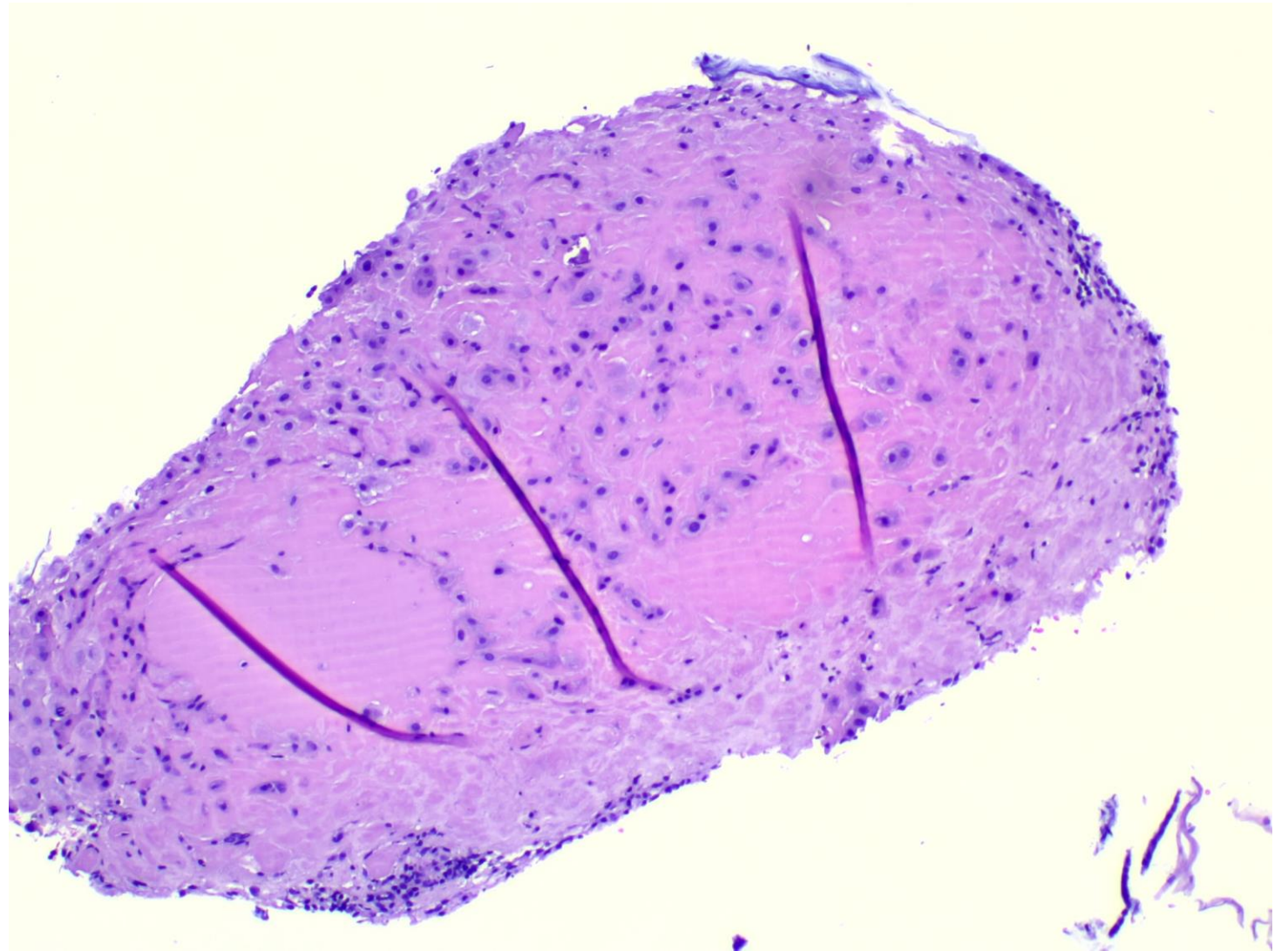
Picture quiz

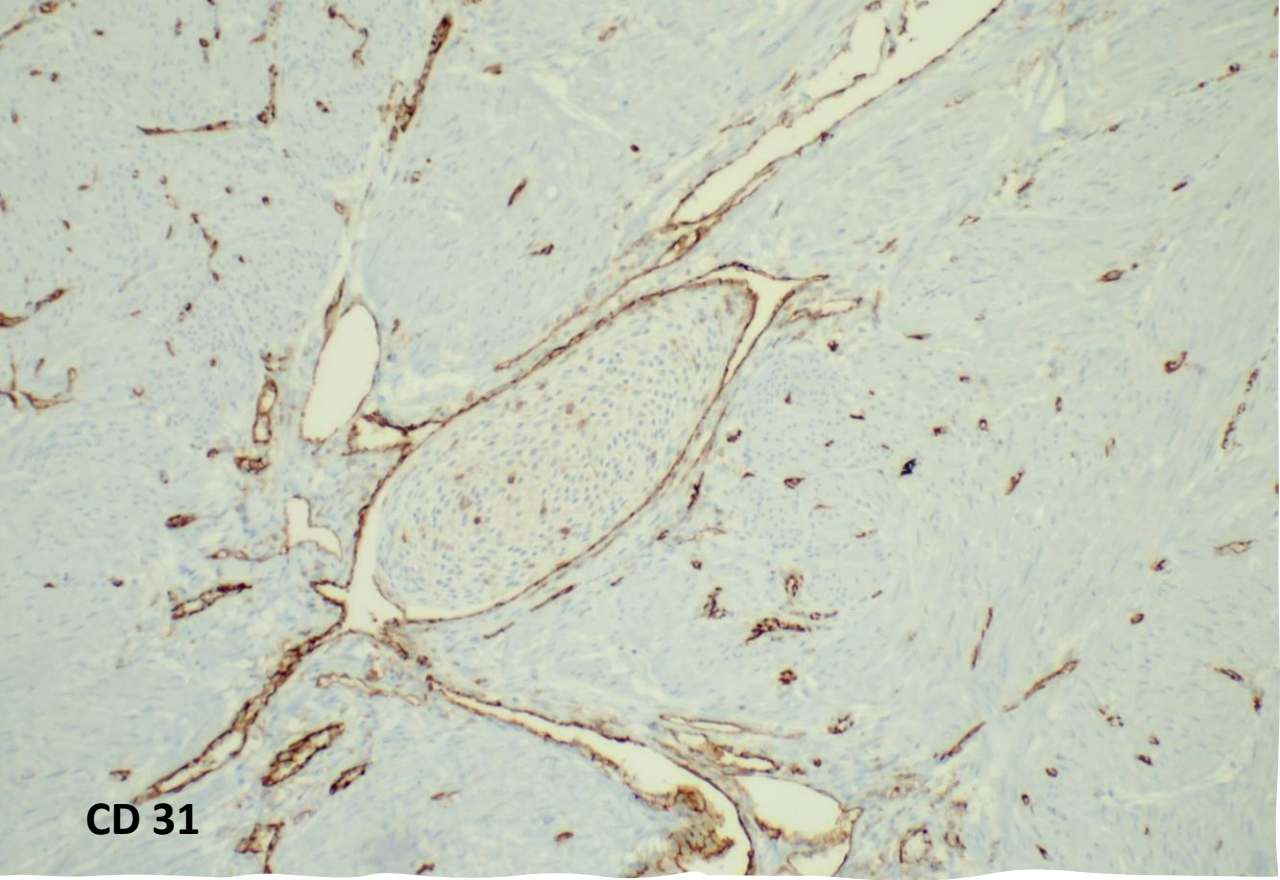
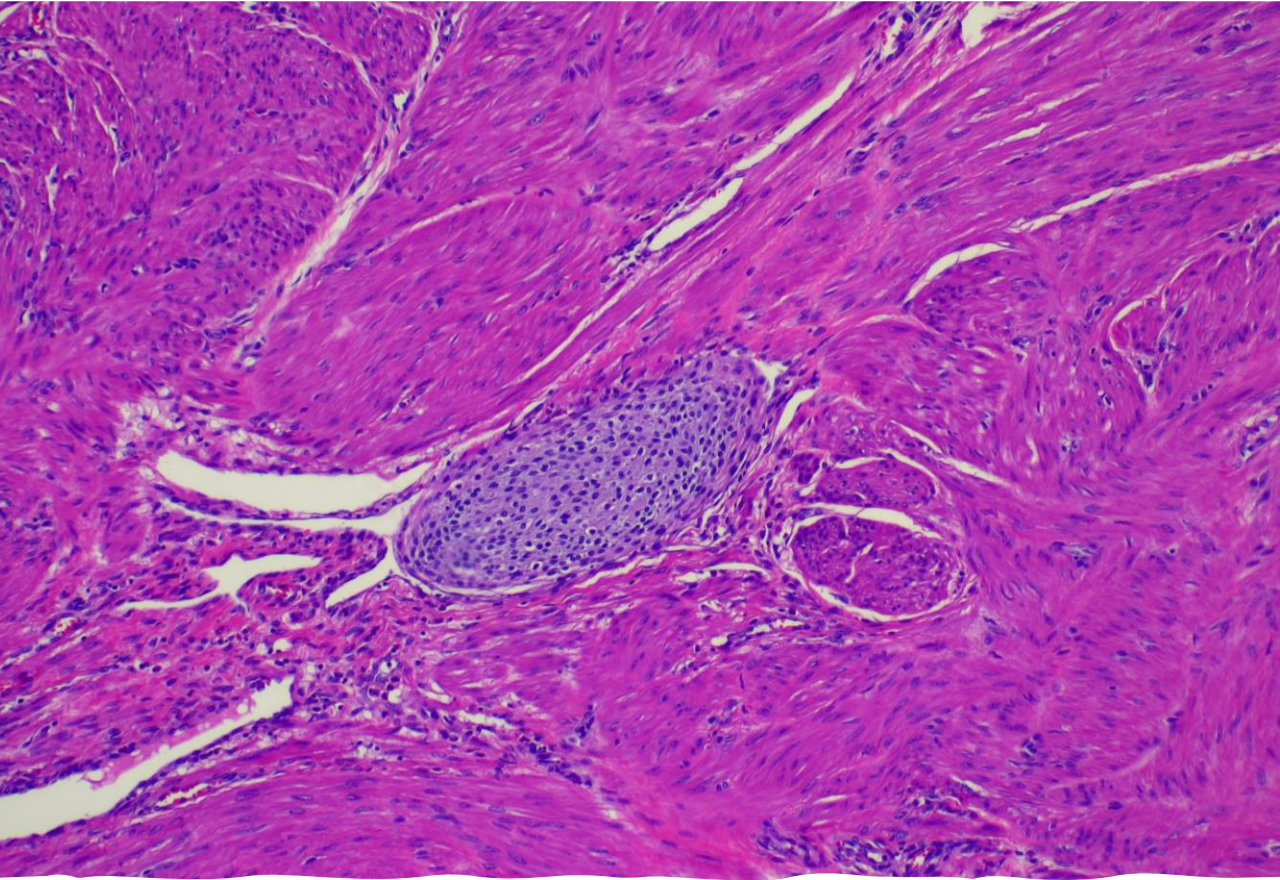
Ritu Bhalla

Give your diagnosis for each case

Case 1

- EMC from 49-year-old female presenting with menorrhagia.





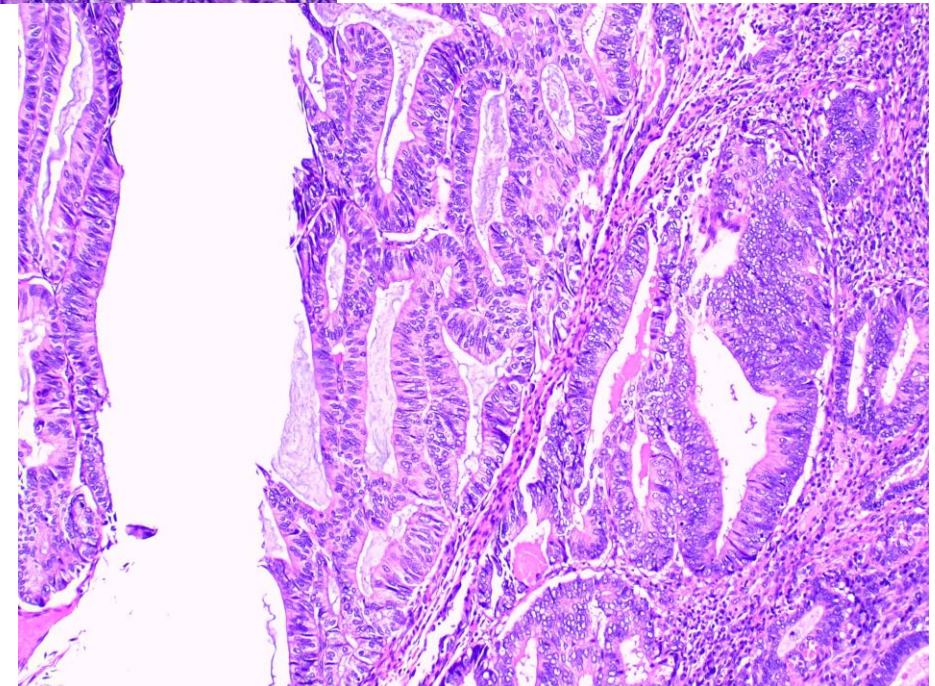
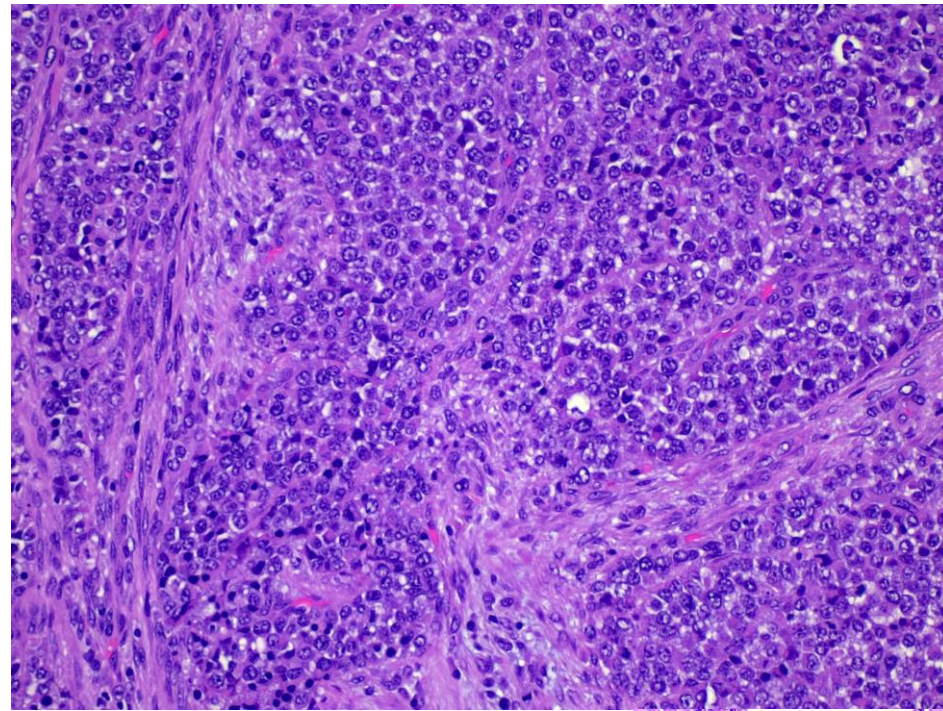
CD 31

Case 2

- Hysterectomy performed for cervical dysplasia, 43-year-old female.

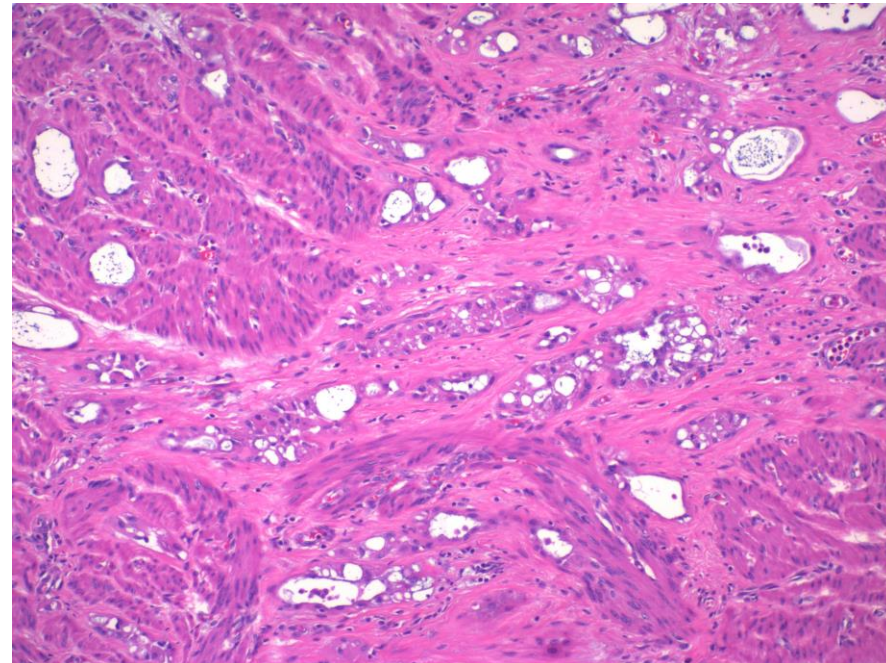
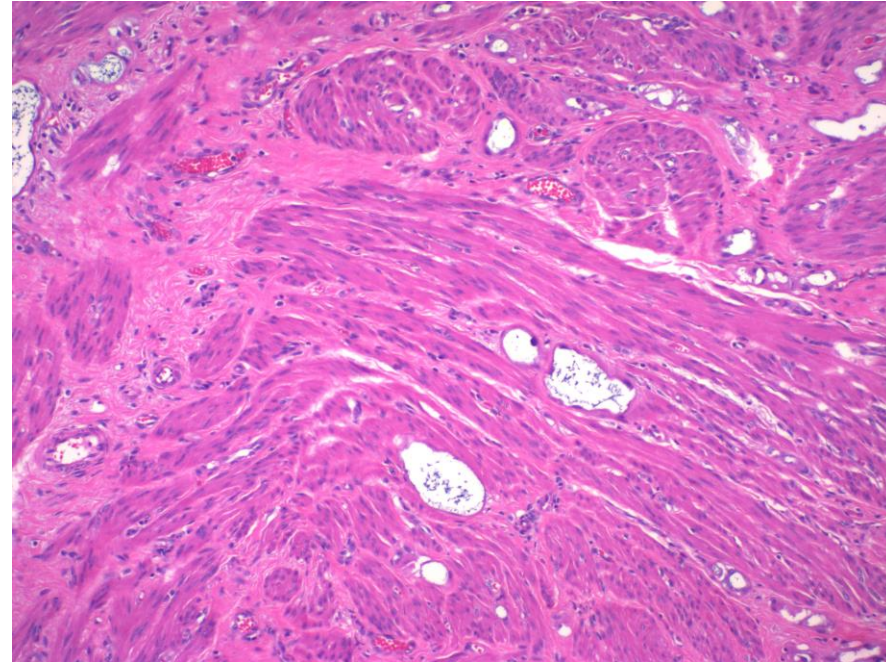
Case 3

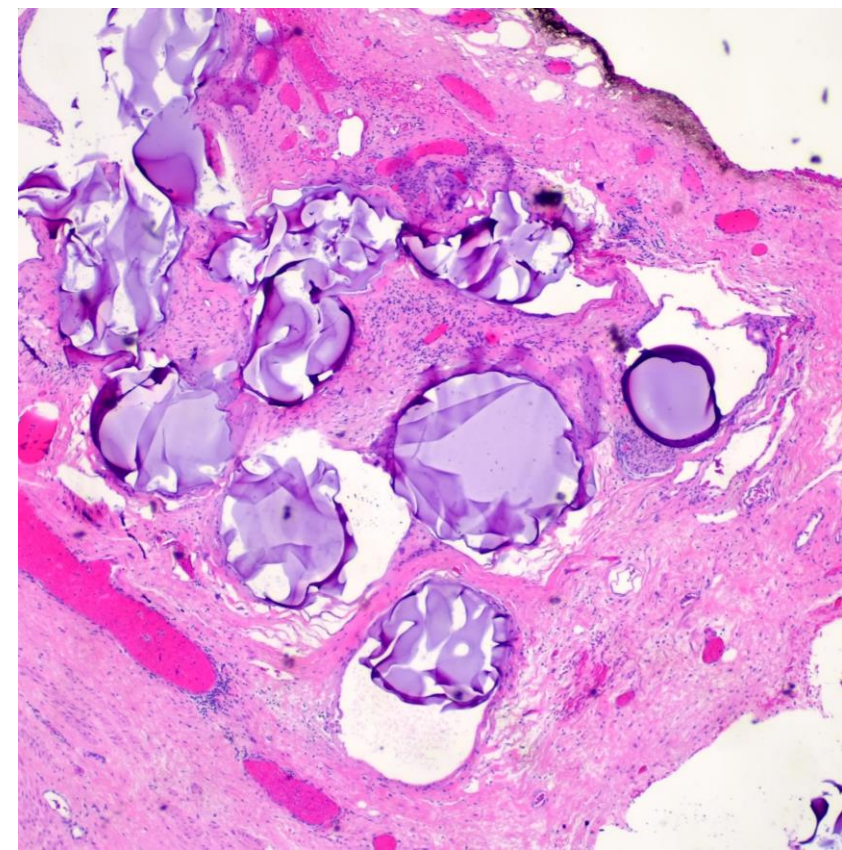
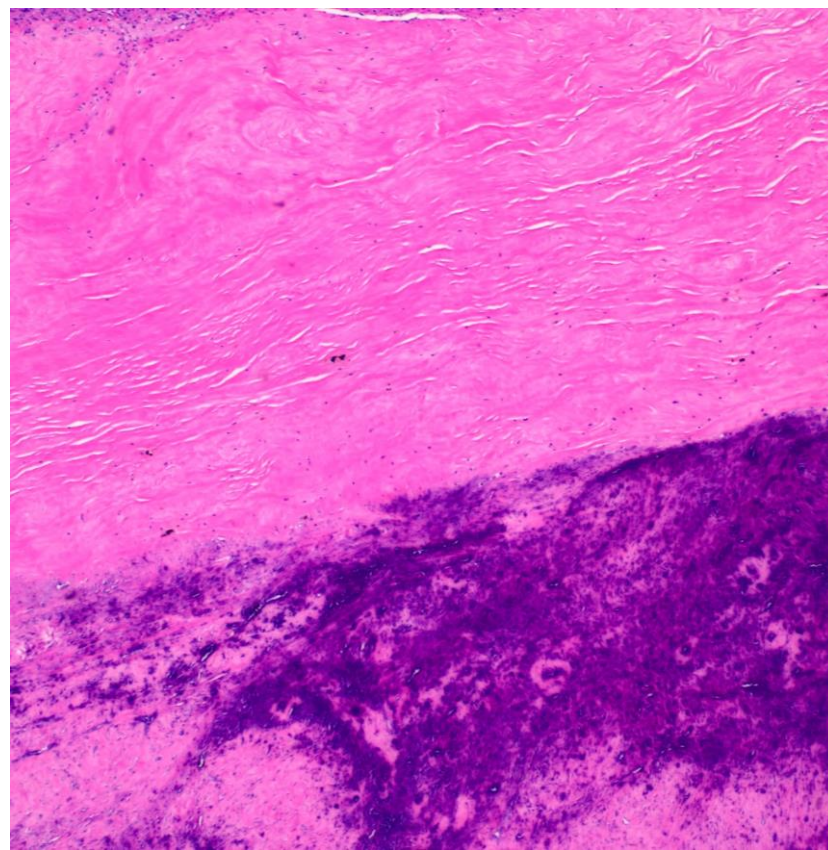
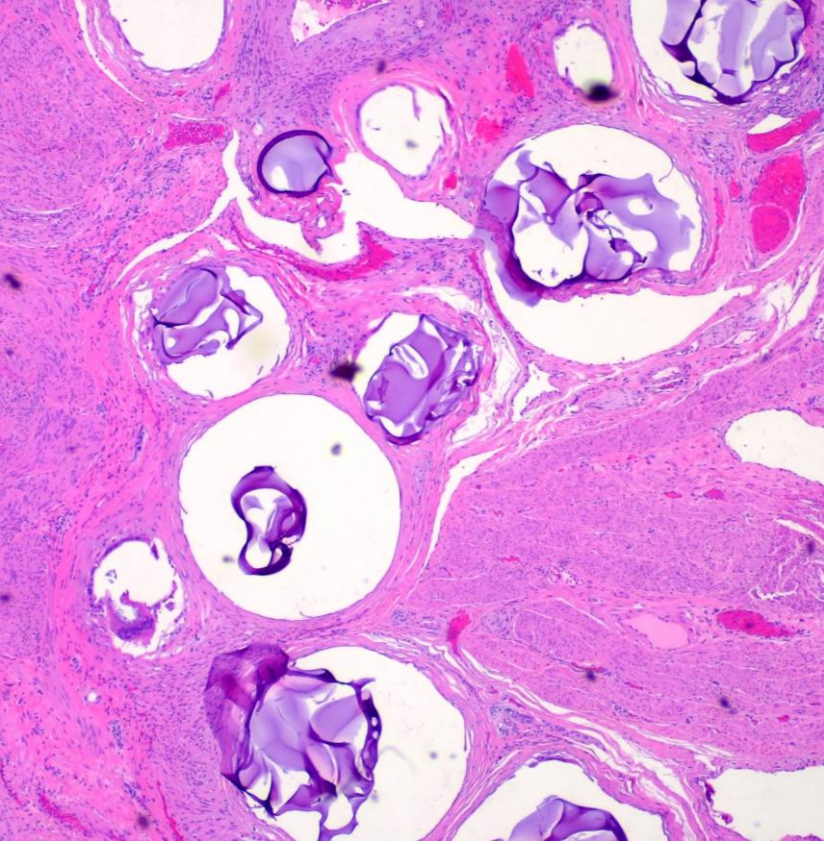
- Hysterectomy from abnormal uterine bleeding 67-year-old female



Case 4

- Hysterectomy from 52-year-old female for cervical prolapse. Finding in cornual myometrium





Case 5:

- Hysterectomy for leiomyoma, 42-year-old female.